

# Managing Resistant Thoracic and Upper Arm Pain: Serratus Anterior Trigger Point and Ultrasound-Guided Fascia Injection

## Dirençli Torasik ve Üst Kol Ağrısının Yönetimi: Serratus Anterior Tetik Noktası ve Ultrason Eşliğinde Fasya Enjeksiyonu

<sup>1b</sup> Demet FERAHMAN<sup>a</sup>, <sup>1b</sup> Soner ARIK<sup>a</sup>, <sup>1b</sup> Mustafa Hüseyin TEMEL<sup>b</sup>, <sup>1b</sup> Fatih BAĞCIER<sup>a</sup>

<sup>a</sup>University of Health Sciences Faculty of Medicine, Başakşehir Çam and Sakura City Hospital,  
Department of Physical Medicine and Rehabilitation, İstanbul, Türkiye

<sup>b</sup>Üsküdar State Hospital, Clinic of Physical Medicine and Rehabilitation, İstanbul, Türkiye

Dear Editor,

Serratus anterior's myofascial pain syndrome is an underrecognized cause of chronic pain that often mimics cardiopulmonary conditions.<sup>1</sup> This muscle, which is essential for scapular stability and thoracic movement, can develop myofascial trigger points (MTrPs) due to repetitive strain, postural dysfunction, or biomechanical stress.<sup>1,2</sup> These MTrPs typically present as localized tenderness along the mid-axillary line with referred pain to the chest, scapular region, and arm, often leading to misdiagnosis.

Treatment options for MTrPs include conservative and interventional approaches aimed at reducing pain and restoring function. Non-invasive strategies involve postural correction, scapular stabilization, and manual therapy. However, in refractory cases, interventions such as dry needling, trigger point injections, or ultrasound-guided fascia injections are considered.<sup>1,2</sup>

The fascial system is a complex network of connective tissue critical for force transmission, proprioception, and pain modulation.<sup>3-5</sup> Dysfunction in this system, including fascial adhesion and fibrosis, has been linked to chronic pain syndromes and reduced mobility.<sup>3-5</sup> Fascia injections improve tissue mobility in patients with chronic pain, postural dysfunction, and work-related musculoskeletal disorders.<sup>3-5</sup> By injecting a solution between the fascial layers, adhesions are disrupted, reducing pain and improving function.

Ultrasound-guided injections into the fascia and interfascial hydrodissection have shown effectiveness for myofascial pain syndrome. Wang et al. introduced the fascial layer-specific hydromanipulation technique, demonstrating that layer-specific hydromanipulation reduces restrictions and increases perfusion.<sup>3</sup> Suarez-Ramos et al. confirmed that interfascial hydrodissection with saline and anesthetic is effective, with notable pain reduction and improved

**Correspondence:** Demet FERAHMAN

University of Health Sciences Faculty of Medicine, Başakşehir Çam and Sakura City Hospital,  
Department of Physical Medicine and Rehabilitation, İstanbul, Türkiye

**E-mail:** demetferahman@gmail.com

Peer review under responsibility of Journal of Physical Medicine and Rehabilitation Science.

**Received:** 11 Mar 2025

**Accepted:** 18 Mar 2025

**Available online:** 25 Mar 2025



range of motion.<sup>4</sup> Similarly, Domingo et al. demonstrated ultrasound-guided interfascial block as a precise technique for trapezius myofascial pain.<sup>5</sup>

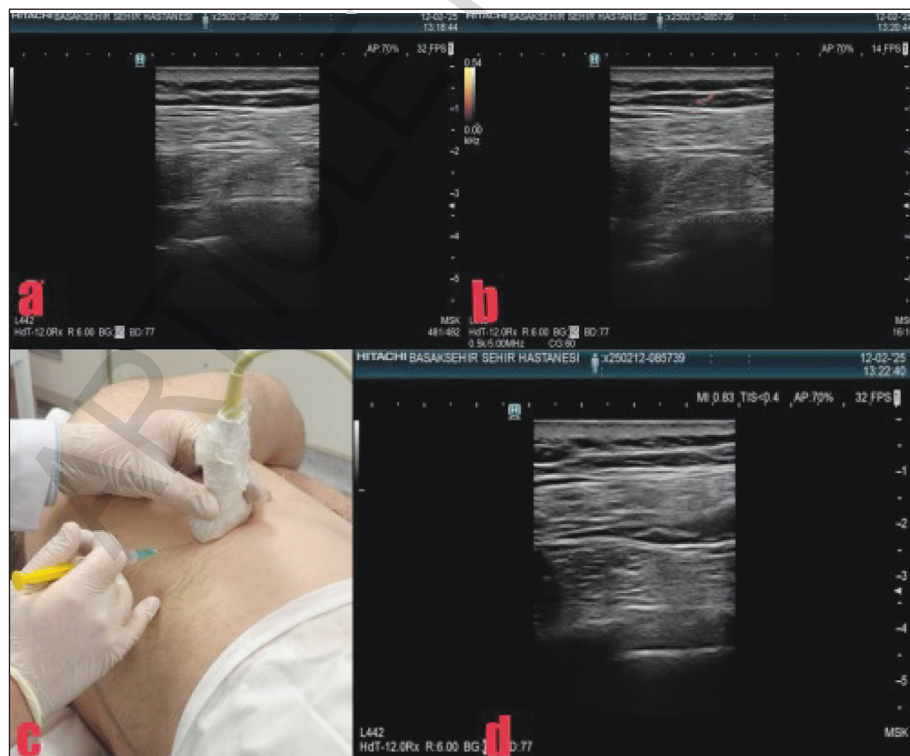
A truck driver presented with three months of persistent right mid-axillary pain radiating through the arm to the fingers. Symptoms worsened with prolonged driving, overhead activities, and deep breathing. He denied trauma, surgery, or systemic illness. Clinical assessment revealed localized tenderness over the serratus anterior, confirmed by pressure algometry at 25 N/cm<sup>2</sup>. Palpation reproduced his characteristic pain. The cervical spine and shoulder exhibited a full range of motion, ruling out radiculopathy or glenohumeral pathology. The radiological and laboratory findings were unremarkable.

The patient was positioned in a side-lying position for optimal ultrasound access to the anterior serratus. A fascia injection targeting the trigger point was performed (Figure 1a, Figure 1b, Figure 1c, Fig-

ure 1d) using 5 mL of 0.9% saline and 5 mL of 1% lidocaine. Three days later, the algometer measurement improved to 35 N/cm<sup>2</sup>, and his Visual Analog Scale pain score decreased from 8 to 3. Given the positive response, a follow-up session was scheduled in 3 weeks, with the possibility of a second injection based on clinical evaluation.

MTrP in the serratus anterior is often overlooked despite its clinical relevance.<sup>1,2</sup> The existing literature primarily focuses on dry needling, local anesthetic-corticosteroid mixtures, and botulinum toxin injections.<sup>1-3</sup> Given its proximity to the lung, ultrasound guidance enhances accuracy, effectiveness, and safety. Visualizing the fascial layers is crucial for precise fascia injection.

In conclusion, fascia injection is a promising treatment that provides targeted pain relief and improves tissue mobility. By addressing fascial dysfunction, this technique offers a valuable approach to musculoskeletal pain management.



**FIGURE 1:** a: Pre-procedural ultrasound image showing the serratus anterior muscle and interfascial plane. b: Ultrasound-guided needle placement targeting the serratus anterior interfascial space. c: Clinical application of ultrasound-guided fascia injection in the side-lying position. d: Post-injection ultrasound image demonstrating successful hydrodissection within the fascial plane.

---

## REFERENCES

1. Bagcier F, Yurdakul OV. A myofascial trigger point of the serratus anterior muscle that could mimic a heart attack: a dry needling treatment protocol. *Acupunct Med.* 2021;39(5):563-4. PMID: 33550825.
2. Vargas-Schaffer G, Nowakowsky M, Eghtesadi M, Cogan J. Ultrasound-guided trigger point injection for serratus anterior muscle pain syndrome: description of technique and case series. *AA Case Rep.* 2015;5(6):99-102. PMID: 26361386.
3. Wang T, Vahdatinia R, Humbert S, Stecco A. Myofascial injection using fascial layer-specific hydromanipulation technique (FLuSH) and the delineation of multifactorial myofascial pain. *Medicina (Kaunas).* 2020;56(12):717. PMID: 33419263; PMCID: PMC7766734.
4. Suarez-Ramos C, Gonzalez-Suarez C, Gomez IN, Gonzalez MK, Co PH, Llamas JA. Effectiveness of ultrasound guided interfascial hydrodissection with the use of saline anesthetic solution for myofascial pain syndrome of the upper trapezius: a single blind randomized controlled trial. *Front Rehabil Sci.* 2023;4:1281813. PMID: 38149112; PMCID: PMC10750391.
5. Domingo T, Blasi J, Casals M, Mayoral V, Ortiz-Sagrístá JC, Miguel-Pérez M. Is interfascial block with ultrasound-guided puncture useful in treatment of myofascial pain of the trapezius muscle? *Clin J Pain.* 2011;27(4):297-303. PMID: 21317780.

ARTICLE IN PRESS