

Two Similar Lines in the Sonographic Evaluation of the Hamstring Muscles: T Junction is the Sonographic Landmark

Hamstring Kaslarının Sonografik Değerlendirmesinde İki Benzer Çizgi: T Kavşağı Sonografik Bir Landmarktır

¹ Burak Tayyip DEDE^a, ² Muhammed OĞUZ^b, ³ Fatih BAĞCIER^c, ⁴ Mustafa Turgut YILDIZGÖREN^d

^aProf. Dr. Cemil Taşcıoğlu City Hospital, Clinic of Physical Medicine and Rehabilitation, İstanbul, Türkiye

^bİstanbul Training and Research Hospital, Clinic of Physical Medicine and Rehabilitation, İstanbul, Türkiye

^cÇam and Sakura City Hospital, Clinic of Physical Medicine and Rehabilitation, İstanbul Türkiye

^dKonya City Hospital, Clinic of Physical Medicine and Rehabilitation, Konya, Türkiye

Keywords: Hamstring; ultrasound; T junction; sonographic landmark

Anahtar Kelimeler: Hamstring; ultrason; T kavşağı; sonografik landmark

Dear Editor

The hamstring muscle complex consists of the biceps femoris, semimembranosus, and semitendinosus muscles originating from the ischial tuberosity, which cause hip extension and knee joint flexion.¹ Hamstring complex is a muscle group prone to injury, mostly in athletes. It has been reported that distal musculotendinous T junction injuries of the biceps femoris may show a different clinical course from other hamstring injuries due to dual innervation and complex anatomy.² The intramuscular ligament structures and the non-uniform structure of the muscles in this region cause anatomical complexity in this region. This makes sonographic evaluation of the hamstring complex difficult.³ However, knowing the sonographic landmarks while evaluating the ham-

string complex may facilitate the evaluation of the complex anatomy and may save time in terms of the diagnosis of pathologies.⁴ Therefore, learning these landmarks is very important especially for inexperienced clinicians who are new to musculoskeletal ultrasonography and may accelerate the learning curve.

In this article, we present that the T junction between the long head and short head of the biceps femoris can be used as a sonographic landmark. The biceps femoris is a two-headed muscle located most lateral to the hamstring complex. The long head starts from the ischial tuberosity, while the short head starts from the linea aspera, lateral intermuscular septum and lateral supracondyle. The two heads are in contact with each other in the distal thigh.²

Correspondence: Burak Tayyip DEDE

Prof. Dr. Cemil Taşcıoğlu City Hospital, Clinic of Physical Medicine and Rehabilitation, İstanbul, Türkiye

E-mail: drbrk22.94@gmail.com

Peer review under responsibility of Journal of Physical Medicine and Rehabilitation Science.

Received: 05 Jun 2024

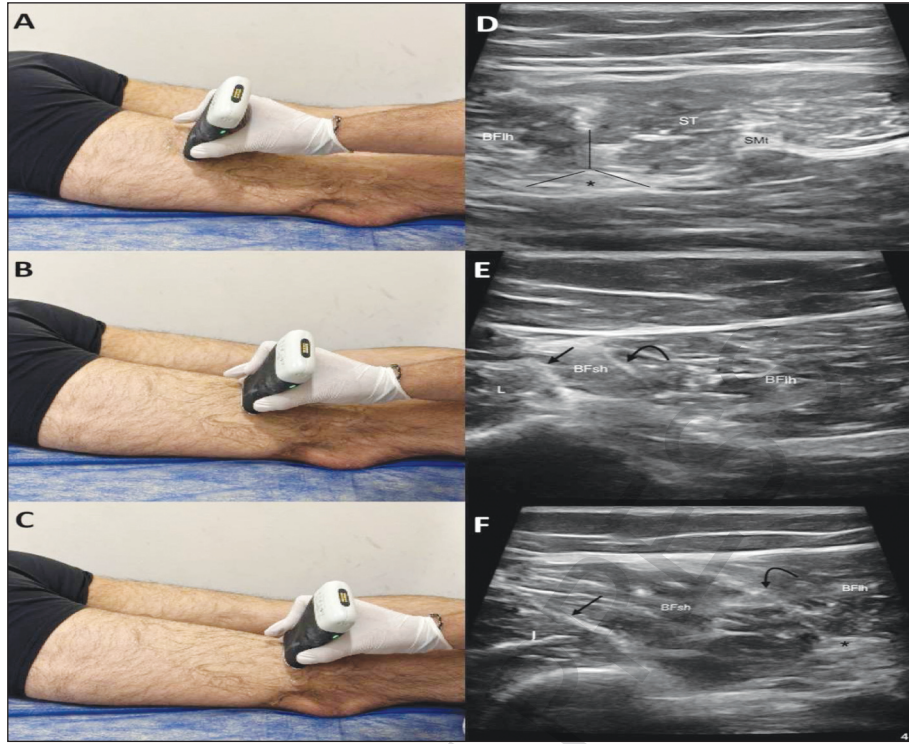
Accepted: 04 Sep 2024

Available online: 10 Sep 2024

1307-7384 / Copyright © 2024 Turkey Association of Physical Medicine and Rehabilitation Specialist Physicians. Production and hosting by Türkiye Klinikleri.

This is an open access article under the CC BY-NC-ND license (<https://creativecommons.org/licenses/by-nc-nd/4.0/>).





ŞEKİL 1: Sonographic evaluation of the hamstring complex. **A, D)** The common tendon of the Semitendinosus (ST) and the long head of the Biceps Femoris (BFih) in the axial plane in the proximal posterior region of the probe and the sciatic nerve at the center of the triad (*); **B, E)** When the probe is moved laterally and slightly distally, two parallel lines appear, the fascia between the short head of the biceps femoris (BFsh) and the lateral compartment (arrow) and the T junction between the short head of the biceps femoris and the long head of the biceps femoris (BFih) (curved arrow); **C, F)** When the probe is moved more distally, two parallel lines become clear, T junction between the long and short head of the biceps femoris (curved arrow) and the sciatic nerve (*).

When evaluating the hamstring complex with ultrasound, the conjoint tendon, which is the common tendon of the biceps femoris long head and semitendinosus, is visualized in the axial plane in the posterior region. The sciatic nerve is very closely associated with the conjoint tendon. After visualizing the long head of the biceps femoris located lateral to the conjoint tendon, when the probe is moved distally, the short head of the biceps femoris starts to be visualized between the line aspera and the long head of the biceps femoris.³ At the point where the short head of the biceps femoris becomes prominent, the T junction can be distinguished from the long head of the biceps femoris. At this point, the other sonographic line that can be considered parallel to the T junction is the fascia between the short head of the biceps femoris and the lateral compartment. These two lines are sonographically visualized parallel to each other. These two parallel lines can be considered as landmarks and can be

useful in identifying the biceps femoris muscles. Here, it can be seen that the fascia between the short head of the biceps femoris and the vastus lateralis muscle is associated with the line aspera of the femur and the T junction is associated with the sciatic nerve (Figure 1).

In conclusion, we think that the short head of the biceps femoris is located between the structures visualized as two parallel lines and can be easily distinguished from the long head by the T junction. Clinicians can use these two parallel lines as landmarks when evaluating the hamstring complex with ultrasound.

Source of Finance

During this study, no financial or spiritual support was received neither from any pharmaceutical company that has a direct connection with the research subject, nor from a company that provides or produces medical instruments and materials which may negatively affect the evaluation process of this study.

Conflict of Interest

No conflicts of interest between the authors and / or family members of the scientific and medical committee members or mem-

bers of the potential conflicts of interest, counseling, expertise, working conditions, share holding and similar situations in any firm.

REFERENCES

1. Becciolini M, Bonacchi G, Bianchi S. Ultrasound features of the proximal hamstring muscle-tendon-bone unit. *J Ultrasound Med.* 2019;38:1367-82. PMID: 30260012.
2. Entwisle T, Ling Y, Splatt A, et al. Distal musculotendinous T junction injuries of the biceps femoris: an MRI case review. *Orthop J Sports Med.* 2017;5:2325967117714998. PMID: 28795071; PMCID: PMC5524253.
3. Balias R, Pedret C, Iriarte I, et al. Sonographic landmarks in hamstring muscles. *Skeletal Radiol.* 2019;48:1675-83. PMID: 30997529; PMCID: PMC6776567.
4. Fee C, Sergot L, Kho J, et al. Ultrasound assessment of the hamstrings complex of athletes with MRI correlation. *Clin Radiol.* 2022;77:337-44. PMID: 35241275.

ARTICLE IN PRESS