

# Effect of Biphosphonate Treatment on Femur Head Avascular Necrosis

## Bifosfonat Tedavisinin Femur Başı Avasküler Nekrozu Üzerine Etkisi

<sup>id</sup> Nazlı KARAMAN<sup>a</sup>, <sup>id</sup> Zeliha ÜNLÜ<sup>b</sup>

<sup>a</sup>Department of Physical Medicine and Rehabilitation, University of Health Sciences, Evliya Çelebi Training and Research Hospital, Kütahya, Türkiye

<sup>b</sup>Department of Physical Medicine and Rehabilitation, Celal Bayar University School of Medicine, Manisa, Türkiye

**ABSTRACT** Avascular necrosis (AVN) is a progressive disorder that results in partial or complete death of bone tissue cells due to impaired blood circulation in the bone. The most common etiological factors in AVN formation are alcoholism, corticosteroid use, trauma, sickle cell anemia, systemic lupus erythematosus, and fat embolism. Among these, corticosteroid use is the most crucial risk factor for femoral head AVN development. Promising results regarding the efficiency of bisphosphonates-alendronate in treatment have been reported in a limited number of literature sources. In this article, a patient who developed bilateral AVN of the femoral head due to corticosteroid use after kidney transplantation and received alendronate treatment for 4 years due to osteoporosis is presented. It was thought that alendronate treatment started before the femoral head collapsed provided symptomatic relief in the hip joints.

**Keywords:** Avascular necrosis; bisphosphonates; osteoporosis

**ÖZET** Avasküler nekroz (AVN), kemiğin kan dolaşımının bozulması sonucunda, kemik doku hücrelerinin kısmen veya tamamının ölmesiyle sonuçlanan, ilerleyici bir bozukluktur. AVN oluşumunda en sık karşılaşılan etiyolojik faktörler; alkolizm, kortikosteroid kullanımı, travma, orak hücreli anemi, sistemik lupus eritematozus ve yağ embolisidir. Bunlardan kortikosteroid kullanımı, femur başı AVN oluşumunda en önemli risk faktörüdür. Sınırlı sayıda literatürde, tedavide bifosfonatlar-alendronatın etkinliğine dair umut verici sonuçlar bildirilmiştir. Bu yazıda, böbrek nakli sonrası kortikosteroid kullanımı bağlı bilateral femur başı AVN gelişen ve osteoporoz nedeniyle 4 yıldır alendronat tedavisi alan bir hasta sunuldu. Femur başında çökme olmadan önce başlanan alendronat tedavisinin, kalça eklemlerinde semptomatik rahatlama sağladığı düşünüldü.

**Anahtar Kelimeler:** Avasküler nekroz; bifosfonatlar; osteoporoz

Avascular necrosis (AVN), also known as osteonecrosis, aseptic necrosis, or ischemic necrosis, is a progressive disorder that results in partial or complete death of bone tissue cells as a result of impaired blood circulation in the bone.<sup>1</sup> This condition, which is most frequently seen in the femoral head, causes functional loss and disability with the femoral head's collapse.<sup>2</sup> The femoral head collapse is found in 75% of the patients with AVN in the femoral head in the first 3 years and 80% in 4 years.<sup>3</sup> The most common etiological factors in AVN formation are alcoholism, corticosteroid use, trauma, sickle cell anemia, systemic lupus

erythematosus, and fat embolism. Among these, corticosteroid use is the most crucial risk factor for femoral head AVN development.<sup>4</sup> Non-surgical treatments are applied in early-stage femoral head AVN. Promising results regarding bisphosphonates-alendronate efficiency in treatment have been reported in a limited number of studies in the literature.<sup>1</sup> The effect of alendronate on the clinical involvement of AVN in a patient who developed bilateral AVN in the femoral head due to corticosteroid use after kidney transplantation and who received alendronate treatment for osteoporosis for four years was evaluated.

**Correspondence:** Nazlı KARAMAN

Department of Physical Medicine and Rehabilitation, University of Health Sciences, Evliya Çelebi Training and Research Hospital, Kütahya, Türkiye

**E-mail:** naz\_cakl@hotmail.com



Peer review under responsibility of Journal of Physical Medicine and Rehabilitation Science.

**Received:** 30 Apr 2022

**Accepted:** 13 Dec 2022

**Available online:** 19 Dec 2022

1307-7384 / Copyright © 2023 Turkey Association of Physical Medicine and Rehabilitation Specialist Physicians. Production and hosting by Türkiye Klinikleri.

This is an open access article under the CC BY-NC-ND license (<https://creativecommons.org/licenses/by-nc-nd/4.0/>).

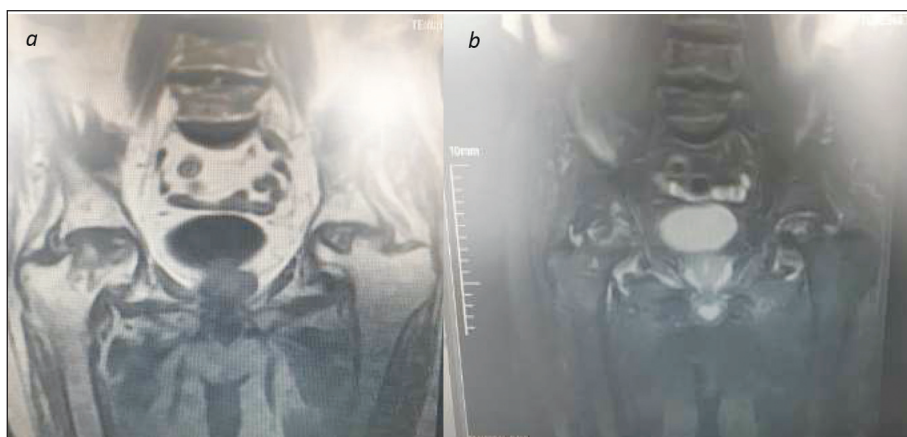
## CASE REPORT

A 72-year-old male patient was admitted to our out-patient clinic with bilateral hip pain for the last 3 months. He stated that the pain spread to both anterior thighs and increased with walking and decreased with rest and warm application. The patient did not report night pain, morning stiffness, loss of appetite, or fatigue. No polymyalgia rheumatica findings were found. There was no history of trauma, alcohol, or smoking. When the patient's medical history was questioned, it was learned that he had hypertension and coronary artery disease. He underwent coronary by-pass surgery nine years ago. He had undergone hemodialysis for 16 years due to kidney failure and had a kidney transplant eight years ago. The patient used a medium dose of prednisolone (20 mg/day) for 5 months after kidney transplantation. Low-dose prednisolone (10 mg/day) was continued for 3 months. The patient stated that he had been using a very low prednisolone dose (2.5 mg/day) for 7 years. The patient, who used alendronate 70 mg/week for osteoporosis diagnosis for 4 years, was not receiving alendronate treatment for the last year.

Detailed musculoskeletal and neurological examinations of the patient were performed. The FABER test (flexion abduction external rotation) was positive (limited) in both hip joints, but the range of motion was painless at the end. There was no limita-

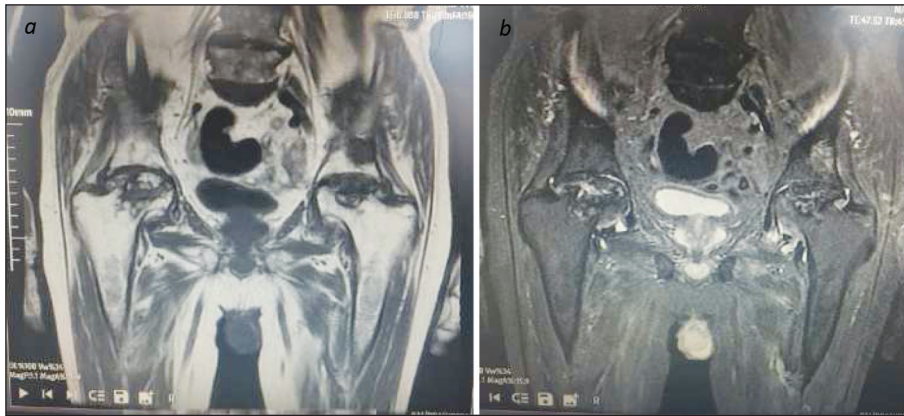
tion of motion, active arthritis, or warmth in the other joints. Neurological examination was normal. The femoral neck T-score was found to be -2.4 in the bone mineral density measurement of the patient. The FRAX score (fracture risk assessment tool) was calculated as 6.9% for hip fracture and 12% for major osteoporotic fracture. In the patient's biochemical tests, the results were as follows: vitamin D 14 ng/L (normal: 30-100), calcium 9.4 mg/dL (normal: 8.8-10.6), phosphorus 3.4 mg/dL (normal: 2.5- 4.5), parathormone 118 ng/L (normal: 12-88), alkaline phosphatase 79 IU/L (normal: 30-120), urea 31 mg/dL (normal: 17-43), creatinine 1.02 mg/dL (normal: 0.81-1.44), C-reactive protein 4 mg/L (normal: 0-5), sedimentation 25 mm/hour (normal: 0-30).

In the lumbar and dorsal plain radiographs of the patient, multiple compression fractures and level losses were detected in the vertebral corpus due to osteoporosis. The typical radiological appearance was not observed for Paget's disease or osteomalacia. It was recommended that the patient should be evaluated in terms of AVN, which was stated to have edema and heterogeneous appearance in the femoral heads in both hip joint magnetic resonance imaging (MRIs) scanned 4 years ago (Figure 1a, Figure 1b). It was reported that the views on the patient's repeated up-to-date hip MRIs were compatible with AVN (Figure 2a, Figure 2b).



**FIGURE 1:** In coronal T1 **a)** and T2 **b)** weighted MRI images of the patient four years ago, edema and heterogeneous appearance in both femoral heads, mild flattening on the femoral heads as more pronounced on the left side, and fluid increase in both coxo femoral joints were observed.

MRI: Magnetic resonance imaging.



**FIGURE 2:** Current coronal T1 **a)** and T2 **b)** weighted MRI showed deformation of both femoral heads, joint surface irregularity, nonhomogeneous hypointense lesion areas at T1 **a)**, and nonhomogeneous hyperintense lesions at T2 **b)**, compatible with AVN.  
MRI: Magnetic resonance imaging; AVN: Avascular necrosis.

The patient was diagnosed with osteoporosis and bilateral femoral head AVN based on physical examination and test results. Alendronate 70 mg/week, calcium 600 mg bid, and 50,000 IU vitamin D<sub>3</sub> per week (for 8 weeks) were given to the patient because of osteoporosis. Orthopedic consultation was requested due to AVN. The patient, who did not accept surgical treatment, was taken up to clinical follow-up. Verbal and written informed consent were obtained from the patient for publication of images and data.

## DISCUSSION

Mineral and bone disorders such as hypophosphatemia, hypercalcemia, hyperparathyroidism, osteomalacia, osteopenia, osteoporosis, and AVN are common in kidney transplant recipients.<sup>5</sup> Our patient had undergone kidney transplantation 7 years ago and received long-term steroid treatment. Considering the patient's age (over 70 years) and risk factors, senile and renal disease were considered as osteoporosis secondary to cortisone use. The bisphosphonate treatment recommended for the patient in primary care was arranged. The golden standard method in the diagnosis of AVN is MRI.<sup>2</sup> The clinical and radiological findings of our case were compatible with AVN.

Before using modern immunosuppressive drugs, AVN was detected in one-third of the transplant patients.<sup>6</sup> It was reported that AVN incidence has de-

creased below 5% with the use of calcineurin inhibitors instead of corticosteroids in recent years.<sup>5,6</sup> The mechanism of AVN that develops in kidney transplant patients is still not elucidated. In the literature, the use of corticosteroids appears to be the highest risk factor for AVN formation.<sup>2,5-7</sup> AVN may develop after long-term treatment with corticosteroids or short-term exposure to high doses.<sup>7</sup> No additional etiological factors that could lead to AVN were found in the patient. Therefore, it was concluded that AVN developed due to corticosteroid use.

Deformation and collapse due to AVN were detected in the bilateral femoral head of the patient. However, AVN involvement in both femoral heads was seen in its early period in MRI 4 years ago. The patient used alendronate for osteoporosis during this period. Bilateral moderate hip pain of the patient who had stopped taking the drug for the last year developed in the last 3 months. In light of this information, it was concluded that alendronate treatment was beneficial for the complaints in femoral head AVN. Most likely, further deformation of the femoral head was delayed until the last year the drug was discontinued. Recently, the use of bisphosphonates in AVN treatment has been recommended in a limited number of studies. The positive effects of bisphosphonates have been attributed to their inhibitory effects on osteoclasts.<sup>1</sup> It was reported that alendronate treatment has positive short-term efficacy in reducing pain, im-

proving joint function, slowing the progression of bone collapse, and delaying the need for total hip arthroplasty for adult AVN patients.<sup>8,9</sup> In a study conducted by Agarwala et al., 395 hips with femoral head AVN were followed for 4 years.<sup>9</sup> The patients were given alendronate 10 mg/day for 3 years. As a result, alendronate was found to improve clinical functions and decrease the need for total hip replacement. It was reported that these positive effects occur when alendronate treatment is given without collapse of the femoral head. In our case, alendronate treatment, which was initiated before the collapse of the femoral head, provided symptomatic relief in the hip joints in line with the recommendations regarding its effectiveness in AVN. Nifedipine, iloprost, and hyperbaric oxygen treatment have been tried in AVN treatment, but no significant benefits have been found.<sup>10</sup> Al-

though our patient did not want surgical treatment, options range from arthrodesis to arthroplasty. Arthrodesis causes severe activity limitation. The results of arthroplasty are good, but patients will need revision surgery in the future when operated on at a young age. Treatments that stop the disease's progression and eliminate the need for surgery until the late arthritic period of AVN are needed. In this context, alendronate treatment can be a glimmer of hope.

Femoral head AVN is a significant cause of morbidity that can cause disability. Kidney transplant recipients presenting with hip pain are at risk of developing AVN due to corticosteroid use. Alendronate treatment to be initiated at an early period can prevent AVN-related complaints and complications. There is a need for further clinical studies to be conducted in large series on this subject.

## REFERENCES

1. Cardozo JB, Andrade DM, Santiago MB. The use of bisphosphonate in the treatment of avascular necrosis: a systematic review. *Clin Rheumatol.* 2008;27:685-8. [[Crossref](#)] [[PubMed](#)]
2. Chang C, Greenspan A, Beltran J, et al. Osteonecrosis. Kelley and Firestein's Textbook of Rheumatology. 2017;1764-87. [[Crossref](#)] [[PubMed](#)] [[PMC](#)]
3. Arai R, Takahashi D, Inoue M, et al. Efficacy of teriparatide in the treatment of nontraumatic osteonecrosis of the femoral head: a retrospective comparative study with alendronate. *BMC Musculoskelet Disord.* 2017;18:24. [[Crossref](#)] [[PubMed](#)] [[PMC](#)]
4. Çalapkulu M, Kızılgül M, Sencar ME, et al. Avascular necrosis of the femoral head due to low-dose corticosteroid used in a patient with panhypopituitarism: a case report and literature review. *Jt Dis Relat Surg.* 2020;31:390-4. [[Crossref](#)] [[PubMed](#)] [[PMC](#)]
5. Vangala C, Pan J, Cotton RT, et al. Mineral and bone disorders after kidney transplantation. *Front Med (Lausanne).* 2018;5:211. [[Crossref](#)] [[PubMed](#)] [[PMC](#)]
6. Felten R, Perrin P, Caillard S, et al. Avascular osteonecrosis in kidney transplant recipients: Risk factors in a recent cohort study and evaluation of the role of secondary hyperparathyroidism. *PLoS One.* 2019;14:e0212931. [[Crossref](#)] [[PubMed](#)] [[PMC](#)]
7. Weinstein RS. Glucocorticoid-induced osteonecrosis. *Endocrine.* 2012;41:183-90. [[Crossref](#)] [[PubMed](#)] [[PMC](#)]
8. Luo RB, Lin T, Zhong HM, et al. Evidence for using alendronate to treat adult avascular necrosis of the femoral head: a systematic review. *Med Sci Monit.* 2014;20:2439-47. [[Crossref](#)] [[PubMed](#)] [[PMC](#)]
9. Agarwala S, Shah S, Joshi VR. The use of alendronate in the treatment of avascular necrosis of the femoral head: follow-up to eight years. *J Bone Joint Surg Br.* 2009;91:1013-8. [[Crossref](#)] [[PubMed](#)]
10. Agarwala S, Banavali SD, Vijayvargiya M. Bisphosphonate combination therapy in the management of postchemotherapy avascular necrosis of the femoral head in adolescents and young adults: a retrospective study from India. *J Glob Oncol.* 2018;4:1-11. [[Crossref](#)] [[PubMed](#)] [[PMC](#)]