

# Idiopathic Bilateral Femoral Head Avascular Necrosis and Bilateral Humeral Head Avascular Necrosis

## İdiyopatik Bilateral Femur Başı Avasküler Nekrozu ve Bilateral Humerus Başı Avasküler Nekrozu

<sup>id</sup> Deniz BULUT<sup>a</sup>, <sup>id</sup> Banu DİLEK<sup>b</sup>

<sup>a</sup>Department of Physical Medicine and Rehabilitation, Kütahya University of Health Science Evliya Çelebi Training and Research Hospital, Kütahya, Türkiye

<sup>b</sup>Department of Physical Medicine and Rehabilitation, Dokuz Eylül University Faculty of Medicine, İzmir, Türkiye

**ABSTRACT** Avascular necrosis (AVN), meaning the cellular death of bone, can occur for various reasons. A 34-year-old male patient admitted with pain in the left shoulder was identified with bilateral hip AVN and bilateral shoulder AVN on magnetic resonance imaging. The patient underwent 21 sessions of physical therapy and was started on a rehabilitation program as the prescribed medical treatment. Prior to treatment, the patient reported a pain Visual Analog Scale score of 8, which reduced to 2 after 3 weeks of treatment. We present this case to literature due to the rare coexistence of hip and shoulder AVN and the good response of the patient to conservative treatment.

**Keywords:** Idiopathic avascular necrosis; physical therapy; hip pain; shoulder pain

**ÖZET** Avasküler nekroz (AVN), çeşitli nedenlerle kan akımında bozulma sonucunda ortaya çıkan, kemiğin hücre ölümüdür. Otuz dört yaşındaki erkek hasta, sol omuz ağrısı nedeniyle polikliniğimize başvurdu. Sol omuz manyetik rezonans görüntülemesinde avasküler osteonekroza sekonder sinyal değişiklikleri saptandı. İzlemede, bilateral kalça AVN ve sağ omuzda da AVN saptandı. Hastaya 21 seans fizik tedavi ve rehabilitasyon programı ve medikal tedavi uygulandı. Hasta, tedavi öncesi Görsel Analog Skala değerini 8 olarak belirtirken; 3 hafta süren tedaviden sonra 2 olarak belirtti. Kalça ve omuz AVN birlikteliği nadir görüldüğü için ve konservatif tedaviye iyi yanıt alındığı için bu vakayı sunmak istedik.

**Anahtar Kelimeler:** İdiyopatik avasküler nekroz; fizik tedavi; kalça ağrısı; omuz ağrısı

Osteonecrosis means literally “bon death”, and is referred to also as avascular necrosis (AVN), ischemic necrosis of the bone, aseptic necrosis and subchondral AVN. The pathogenesis of osteonecrosis is complex, but regardless of the mechanism, bone death ultimately occurs as a result of the complete or partial disruption of the delivery of oxygen and/or nutrients to the bone and surrounding tissues.<sup>1</sup>

The etiology of AVN has yet to be fully clarified, although etiological factors have been divided

into 2 main groups, being traumatic and non-traumatic, the latter of which represents a fairly large subgroup.<sup>2</sup> Often, no cause can be found for osteonecrosis, and such cases are referred to as idiopathic osteonecrosis.<sup>3</sup>

In the treatment of femoral head AVN, which is a very difficult problem to resolve, the goal is to preserve the existing anatomical structure, for which the age, general condition, comorbidities and disease stage of the patient need to be considered, along with

**Correspondence:** Deniz BULUT

Department of Physical Medicine and Rehabilitation, Kütahya University of Health Science Evliya Çelebi Training and Research Hospital, Kütahya, Türkiye

**E-mail:** denizhava1988@gmail.com



Peer review under responsibility of Journal of Physical Medicine and Rehabilitation Science.

**Received:** 05 May 2021

**Received in revised form:** 06 Mar 2022

**Accepted:** 11 Mar 2022

**Available online:** 04 Apr 2022

1307-7384 / Copyright © 2022 Turkey Association of Physical Medicine and Rehabilitation Specialist Physicians. Production and hosting by Türkiye Klinikleri.

This is an open access article under the CC BY-NC-ND license (<https://creativecommons.org/licenses/by-nc-nd/4.0/>).

other important parameters such as the size and location of the affected segment.<sup>2</sup>

Although there was no clear etiology in the presented case, AVN was detected in more than one joint. One of the basic factors that should be kept in mind in cases of femoral head AVN is that the disease is frequently bilateral, being noted in around 50% of cases.<sup>2</sup> In the presented case, a humeral AVN was detected in addition to bilateral hip AVN, and despite the multiple joint involvement, a reduction in pain was achieved without the need for surgical treatment.

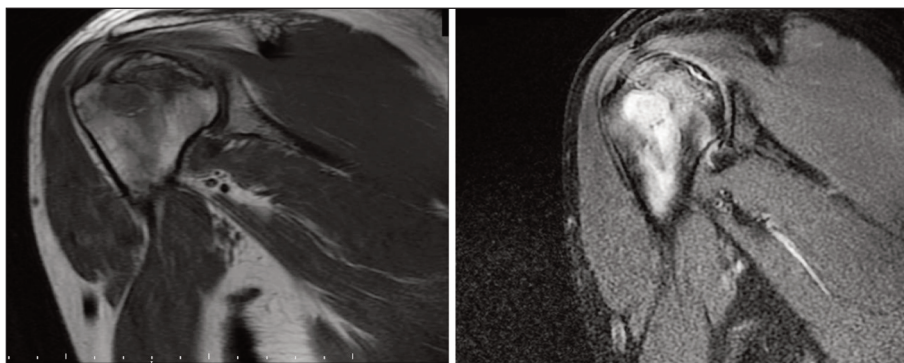
## CASE REPORT

A 34-year-old male patient with no known disease was admitted to our outpatient clinic due to pain in the left shoulder. The patient had been working in ceramics for 1.5 years, before which worked as a security guard. The complained of shoulder pain at rest and at night that increased with movement. There was no fever, no weight loss and no night sweats.

A physical examination revealed a shoulder joint range of flexion of 160/180 degrees, a range of abduction of 150/170 degrees on the left and no other range of motion limitation of the shoulder joint. Shoulder impingement tests were positive and there were no signs of arthritis. The neurological exam was normal, and no apparent pathology was detected on a shoulder X-ray. After a diagnosis of shoulder impingement syndrome of the left shoulder was made, The magnetic resonance imaging (MRI) of the patient's shoulder revealed hypointense signal changes

on T1-weighted images, and hypointense and hyperintense signal changes on T2-weighted images, compatible with AVN of the humeral head (Figure 1).

As a result, the patient was diagnosed with humeral head AVN with morning stiffness. There was no history or physical examination finding suggesting of active arthritis, no history of drug use and no history of trauma. There was no indication of excessive alcohol or steroid use, no transplantation history, no radiation exposure, no inflammatory bowel disease such as Crohn's disease and no ulcerative colitis. Routine blood tests revealed normal blood lipids, uric acid, serum amylase and parathormone. The patient was consulted with hematology and rheumatology to investigate possible etiological causes, and rheumatoid factor, ANA, ENA panel, anticardiolipin, antiphospholipid, anti-beta-2 glycoprotein, lupus anticoagulant, homocysteine, peripheral smear, immunoglobulin values, computed tomography of the thorax and abdomen for malignancy screening, DXA were requested, the results of which were normal. The patient was consulted with orthopedics. No surgical intervention was considered. He was placed on medical treatment (nonsteroidal anti-inflammatory medication) and was given a home exercise program (light stretching and joint range of motion exercises). The load on the joint was reduced. About 1 month later, the patient was admitted to our outpatient clinic with a pain in the hip spreading to the bilateral thighs. A physical examination revealed no sign of active arthritis, while the FABERE and FADIR tests were positive. A neurological examina-



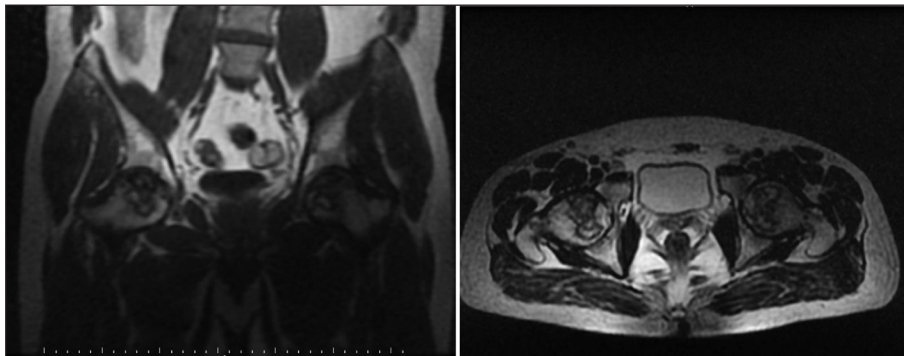
**FIGURE 1:** T1 (right) and STIR sequence (left) images of the left shoulder coronal section T1-weighted series, hypo-, T2-weighted series and hypo-and hyperintense signal changes.

tion revealed no pathology; there was no difference in foot length; and no antalgic gait was detected. An MRI of the hip was requested considering the association between AVN of the hip and shoulder, and revealed changes in signal secondary to Stage-III avascular osteonecrosis in the bilateral hip joint (Figure 2).

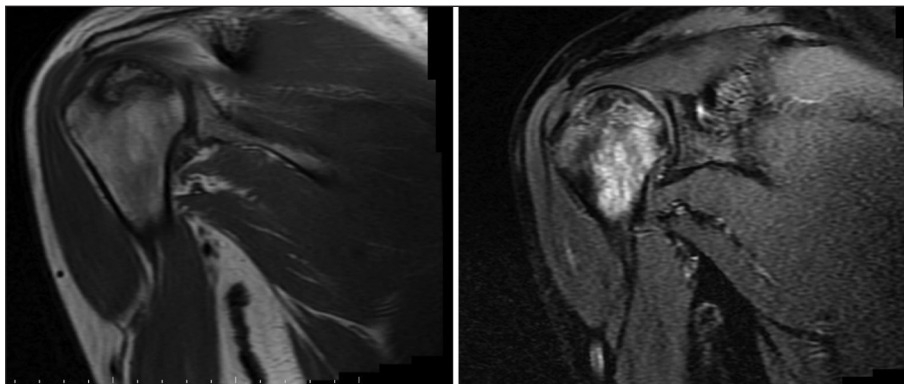
The patient was again consulted with orthopedics, but no surgery was considered. The patient underwent 21 sessions of physical therapy and was started on a rehabilitation program as the prescribed medical treatment [Physical therapy and a rehabilitation program: 15 minute hot package, 3-8 minute ultrasound (1 watt/cm<sup>2</sup>), 20 minute 70 Hz conventional transcutaneous electrical nerve stimulation; medical treatment: nonsteroidal anti-inflammatory drug]. Joint range of motion and light stretching exercises were recommended. The load on the joint was re-

duced through the use of a cane. Prior to treatment, the patient reported a pain Visual Analog Scale (VAS 0-10 cm) score of 8 for the left shoulder and hip, which reduced to 2 after 3 weeks physical therapy program and medical treatment.

The patient had pain in the right shoulder that began during hospitalization and that gradually increased. An MRI of the right shoulder was performed revealing a lesion that appeared to be hypointense on T1-weighted imaging, and hyperintense on T2-weighted images, consistent with broad-based edema with a surrounding sclerotic area (Figure 3). The patient underwent 9 sessions of the same physical therapy and an exercise program, and medical treatment for the right shoulder. The VAS value declined from 6 to 3. The patient's written and verbal consent was obtained for the presentation of his case in a case report.



**FIGURE 2:** Bilateral hip coronal section T1 image (right), and bilateral hip axial section T2 image (left) showed changes in signal secondary to Stage-III avascular osteonecrosis.



**FIGURE 3:** Images of the T1 (right) and STIR sequence (left) in the right shoulder coronal section. A lesion was detected that appeared to be hypointense on T1-weighted imaging, and hyperintense on T2-weighted images, consistent with broad-based edema with a surrounding sclerotic area (big arrow).

## DISCUSSION

Multifocal osteonecrosis is defined as the presence of osteonecrosis at 3 or more osseous sites. It is an infrequent entity, accounting for fewer than 3% of cases involving osteonecrosis patients.<sup>4</sup>

Cases of femoral head AVN can be divided into 2 main groups based on the etiology (traumatic and non-traumatic). The non-traumatic group includes cases of systemic steroid use, excessive alcohol use, pregnancy, hyperlipidemia, Caisson's disease, organ transplantation, radiation exposure, hematological diseases, gout, hyperparathyroidism, inflammatory bowel diseases and pancreatitis.<sup>2</sup> All such causes were investigated in our patient, but no etiological cause could be identified.

Clinically, patients most often complain of increased pain under load that can spread to the lower back, groin and thigh. Some patients may complain of night pain due to the increase in intraosseous pressure as a result of venous stasis.<sup>5</sup> In patients with involvement in both hips, the asymptomatic period for the second hip is 4.6-5.5 years.<sup>6</sup> Our patient had an additional complaint of pain that increased with load, occurring also occasionally at night, and pain in both hips that began at the same time.

In the early diagnostic stages, an abnormal finding may not be detected on a direct graph. The most advantageous diagnostic approach in such cases are MRI and bone scintigraphy.<sup>7</sup> In our patient, no obvious pathology was identified in the direct graph at the outset, but with the continuation of pain, the diagnosis was supported by MRI and clinical findings.

A physical therapy and rehabilitation program can provide relief and alleviate some symptoms, but will not necessarily prevent progression in the progressive hip AVN. Similarly, limiting the weight carried through the use of assistive devices such as crutches or canes can be useful in controlling the symptoms of pain, weakness and walking. Nonsteroidal anti-inflammatory drugs and acetaminophen can provide temporary pain relief in symptomatic patients.<sup>8</sup> Loading was reduced through the use of auxiliary devices in the present

case, and a significant reduction in pain was achieved through a physical therapy and rehabilitation program, and the use of non-steroidal anti-inflammatory drugs.

In a previous case report, idiopathic widespread femoral osteonecrosis was reported to be an uncommon cause of knee pain.<sup>9</sup>

In a further study involving a case of idiopathic osteonecrosis of the knee in a 31-year-old female patient, it was stated that good clinical results could be achieved with conservative treatment in cases of early-stage spontaneous osteonecrosis. Similar to this case, no etiological factor was identified in the present study, and full recovery was achieved with conservative treatment.<sup>10</sup>

In the present case, no etiological factor could be identified, while bilateral humerus involvement in addition to bilateral hip involvement were identified, similar to that reported in a study in which bilateral idiopathic hip osteonecrosis was found in a 50-year-old male patient.<sup>11</sup>

In patients with asymptomatic AVN, there is a high prevalence of progression to symptomatic disease and the collapse of the femoral head. For patients with asymptomatic disease, education is essential to ensure the reduction of risk factors and the improvement of care. Patients diagnosed with early-stage AVN should be advised to avoid placing excessive pressure on their joints, to follow a healthy diet and to maintain an appropriate weight if they are to reduce the progression of osteonecrosis.<sup>8</sup> We informed our patient about his disease, investigated the underlying etiological factors and continued the monitoring of progression.

In the present case, AVN was detected in more than one joint, and a good response was obtained to conservative treatment. Since no etiological factors could be detected, we identified it as idiopathic, although the patient's occupation and mechanical factors may have played a facilitating role.

When AVN is detected in the hip or shoulder, it should be kept in mind that there may be AVN in the joint if pain is reported in other joints.

## REFERENCES

1. Chang C, Greenspan A, Gershwin ME. Osteonecrosis. In: Firestein G, Budd R, Gabriel S, McInnes I, O'Dell J, eds. *Kelley's Textbook of Rheumatology*. 9th ed. Philadelphia: Elsevier/Saunders; 2013. p.1692-711. [[Crossref](#)] [[PubMed](#)] [[PMC](#)]
2. Ozdemir H, Baloğlu M. Femur başının avasküler nekrozu: tanı ve tedavisi [Avascular necrosis of the femoral head: diagnosis and treatment]. *TOTBİD Dergisi*. 2010;9(1):41-51. [[Link](#)]
3. Iğdek S, Onay T, Kütük E. Bilateral avascular necrosis of femoral heads associated with pregnancy: a case report and review of literature. *Turk J Osteoporos*. 2018;24:108-11. [[Crossref](#)]
4. Gallart Úbeda V, Elía Martínez JM, Puerta de Diego R, et al. [Multiple osteonecrosis. Update and case report]. *Rehabilitacion (Madr)*. 2020;54(1):63-7. [[Crossref](#)] [[PubMed](#)]
5. Pajaczkowski JA. The stubborn hip: idiopathic avascular necrosis of the hip. *J Manipulative Physiol Ther*. 2003;26(2):107. [[Crossref](#)] [[PubMed](#)]
6. Rizzo M, Urbanak JR. Osteonekroz. Tan K, Taşkaynatan MA, çeviri editörleri. In: Harris ED, Budd CR, Genovese MC, Firestein GS, Sargent JS, Sledge CB, eds. *Kelly Romatoloji*. 7. Baskı. Ankara:Güneş Kitabevi; 2006. p.1812-28.
7. Imhof H, Breitscheher M, Trattng S, et al. Imaging of avascular necrosis of bone. *Eur Radiol*. 1997;7(2):180-6. [[Crossref](#)] [[PubMed](#)]
8. Lespasio MJ, Sodhi N, Mont MA. Osteonecrosis of the hip: a primer. *Perm J*. 2019;23:18-100. [[Crossref](#)] [[PubMed](#)] [[PMC](#)]
9. Sayılır S. İdiopathic widespread femoral osteonecrosis: An insidious cause for knee pain. *Turk J Osteoporos*. 2017;23:45-6. [[Crossref](#)]
10. Yener M, Aşkın A, Çerçi S, ve ark. Spontan diz osteonekrozisi: olgu sunumu [Spontaneous knee osteonecrosis: a case report]. *Türkiye Fiziksel Tıp ve Rehabilitasyon Dergisi*. 2010;56:40-2. [[Link](#)]
11. Yağız AE, Üstün N, Güler H, Turhanoğlu AD. Her iki kalçada aynı anda gelişen idiyopatik bilateral avasküler nekroz: olgu sunumu [Bilateral idiopathic avascular necrosis of both hip developing at the same time: case report]. *Mustafa Kemal Üniv Tıp Derg*. 2013;4(14). [[Link](#)]