

# A Rare Cause of Upper Extremity Pain: Cervical Perineural Cyst

## Üst Ekstremitte Ağrısının Nadir Bir Nedeni: Servikal Perinöral Kist

<sup>1b</sup> Hamit GÖKSU<sup>a</sup>, <sup>1b</sup> İlker Fatih SARI<sup>b</sup>, <sup>1b</sup> Halim YILMAZ<sup>c</sup>, <sup>1b</sup> Halil Ekrem AKKURT<sup>d</sup>

<sup>a</sup>Clinic of Algology, Ankara City Hospital, Ankara, TURKEY

<sup>b</sup>Clinic of Physical Medicine and Rehabilitation, Giresun University Prof.Dr. A. İlhan Özdemir Training and Research Hospital, Giresun, TURKEY

<sup>c</sup>University of Health Sciences Konya Training and Research Hospital, Konya, TURKEY

**ABSTRACT** Perineural cysts are commonly incidental and rarely symptomatic and cervical region is an uncommon site. We report a patient with cervical radicular pain whose neurological examination and neuroradiological and electrophysiological evaluations supported the findings of cervical perineural cysts and benefited from medications and physical therapy.

**Keywords:** Perineural cyst; Tarlov cyst; radiculopathy; physical therapy modalities

**ÖZET** Perinöral kistler genellikle rastlantısal olarak farkedilir, nadiren semptomatiktir. Servikal bölge, perinöral kistlerin nadiren görüldüğü yerlerden biridir. Burada servikal radiküler ağrısı olan, nörolojik muayene ile nöroradyolojik ve elektrofizyolojik değerlendirmelerin servikal perinöral kist bulgularını desteklediği, ilaç ve fizik tedavi modalitelerinden yararlanan bir hastayı sunuyoruz.

**Anahtar Kelimeler:** Perinöral kist; Tarlov kisti; radikülopati; fizik tedavi modaliteleri

Perineural cysts, also known as Tarlov cysts, are benign cerebrospinal fluid-filled cysts of the spinal cord. They are commonly seen in sacral spine. Except sacral spine perineural cysts are very rare conditions. Herein we report a symptomatic cervical perineural cyst causing pseudoradiculopathy treated with physical and medical therapy. We aimed that cervical perineural cysts should be considered for upper extremity pain and must be ruled out for differential diagnosis.

### CASE REPORT

We state a Tarlov cyst located in the cervical spine, where Tarlov cysts is very rare. A 44-year-old man

presented with a 6-week history of neck and shoulder pain. He was complaining about pain 8/10 on Visual Analogue Scale (VAS) in the lateral side of his left shoulder, arm and forearm. He had no burning sensation and numbness. There was no history of trauma. As far as his past medical history is concerned, there were no previous diseases and drug use. He was a worker doing head over activities. He had admitted to orthopedic surgeon and left shoulder magnetic resonance imaging showed supraspinatus tendinitis. There was no other pathology. From the history of the patient we learned that he had 20 sessions of physical medicine and rehabilitation program consisting of hot pack, ultrasound, transcuta-

**Correspondence:** Hamit GÖKSU

Clinic of Algology, Ankara City Hospital, Ankara, TURKEY/TÜRKİYE

**E-mail:** hamitgoksu@yahoo.com



Peer review under responsibility of Journal of Physical Medicine and Rehabilitation Science.

**Received:** 5 Jun 2020

**Received in revised form:** 18 Aug 2020

**Accepted:** 25 Aug 2020

**Available online:** 18 Jan 2021

1307-7384 / Copyright © 2021 Turkey Association of Physical Medicine and Rehabilitation Specialist Physicians. Production and hosting by Türkiye Klinikleri.

This is an open access article under the CC BY-NC-ND license (<https://creativecommons.org/licenses/by-nc-nd/4.0/>).

neous electrical nerve stimulation (TENS), shoulder range of motion, strengthening and stretching exercises. But his pain was severe and no improvement detected. Following therapy, he had admitted to our clinic. On examination, cervical range of motion was normal but painful, all deep tendon reflexes were normal. Muscle strength of all upper extremity myotomes was 5/5. Pinprick sensation, light touch sensation, vibration sensation of C5-8, T1 distribution was intact. There was negative response of the Hoffmann's reflex and aggravation of symptoms when tilting the head to the right (opposite direction of the affected nerve root) and hyperabduction. Compression test was negative and distraction test was positive. Shoulder range of motion was decreased for active abduction, but in normal range for other planes. Jobe and Neer tests were positive. Magnetic resonance imaging (MRI) of cervical spine and brachial plexus was requested. The radiologist confirmed there was a small disc bulging and 4 mm perineural cyst near the left neural foramina on the left at C6-7 level (Figure 1A, Figure 1B, Figure 1C). Brachial plexus MRI was normal. Electromyography (EMG) test showed no abnormality; sensory and motor studies of the radial, ulnar, median, lateral antebrachial cutaneous and medial antebrachial cutaneous nerve; needle EMG test of supraspinatus, deltoid, trapezius, biceps brachii, triceps, flexor carpi ulnaris, adductor digiti minimi, abductor pollicis brevis and extensor indicis proprius and paraspinal muscles were normal. The F responses were also normal.

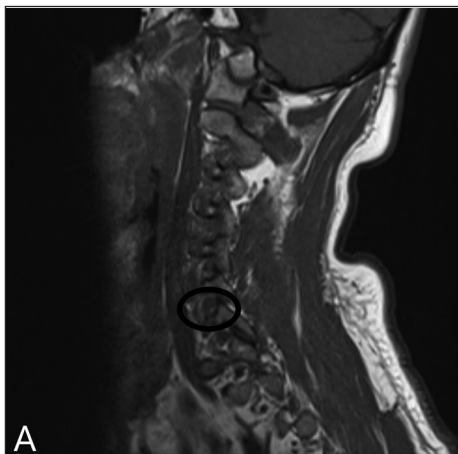

FIGURE 1A: T1 sagittal image.

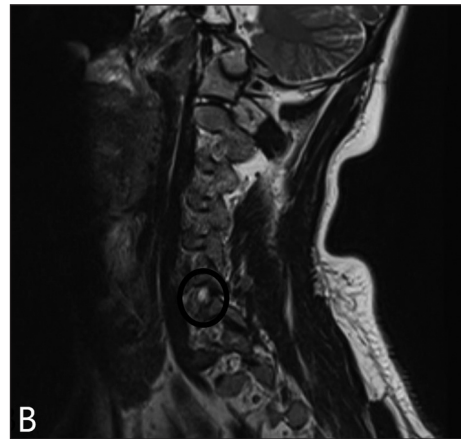


FIGURE 1B: T2 sagittal image.

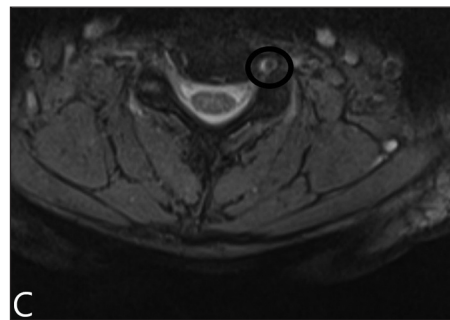


FIGURE 1C: Axial image.

The perineural cyst was considered the cause of the problem as it could explain the patient's symptom. Physical therapy consists of hot pack, ultrasound, TENS and intermittent traction, cervical isometric and posture exercises were applied among 15 sessions. The patient was treated with a 2-week course of non-steroid anti-inflammatory drugs (NSAIDs), tramadol 2x100 mg/day and pregabalin 2x150 mg/day. The patient was consulted to neurosurgery but a surgery was not planned for him. He was asked to limit his activities, especially avoid extreme stretch of his arm and neck, and lifting. After the 3 week-course of conservative therapy, VAS score was 4/10. After initial relief of symptoms, physical therapy and life style changes were suggested. Last follow up after 6 months was preservation of a good improvement with mild pain of the left arm. The patient was described pain only when he had a hard work and satisfied with medical therapy and there was no need for any further action to be considered.

## DISCUSSION

Perineural cysts mostly known as Tarlov cysts named with first descriptor of the cysts begin in the perineural space due to leakage of cerebrospinal fluid into and commonly seen in sacral region.<sup>1</sup> Tarlov cysts are usually asymptomatic and found incidentally. The etiology of these lesions remains contentious. It is believed that they are congenital, or prior surgery or hemorrhage and increased cerebrospinal fluid (CSF) pressure were accused by authors.<sup>2-4</sup> They occur along the nerve roots, at or distal to the junction of the posterior root and the dorsal ganglion.<sup>5</sup> MRI imaging has estimated that Tarlov cysts prevalence is 4.6% to 9% of the population, with an estimated 10% becoming symptomatic at some point during life.<sup>3</sup> Symptomatic cases found in the literature are mostly located at the lumbar and sacral levels of the spine. If symptomatic, they have been reported to cause sacral radiculopathy, hip, leg, foot, or perineal pain, paresthesias, bowel or bladder dysfunction, neck pain, numbness in the arm, and mid-back pain.<sup>6-8</sup> However symptomatic cervical perineural cysts are extremely rare in the literature;

when present they can cause radicular pain, mimic entrapment neuropathies or mimic spinal tumors in imaging studies.<sup>9,10</sup> Treatment option includes medication, transforaminal epidural steroid injections, microscopic surgery, percutaneous fibrin injection, selective dorsal root ganglion blockage.<sup>11-15</sup>

As mentioned above, few reports are available on symptomatic perineural cysts in the cervical spine and it has not been discussed how they should be managed. Like our patient, some benefit from physical therapy and medications; for patients resistant to therapy, another therapy modality like epidural steroid injection, nerve root block and surgery may be considered.<sup>10,15,16</sup>

## CONCLUSION

We would like to point out the clinical significance of perineural cysts and they should be considered in mind. Attempting an initial conservative approach, including using of oral NSAIDs, neuropathic pain medications and physical therapy to any symptomatic perineural cyst, before advancing to any invasive intervention may be very useful.

## REFERENCES

1. Tarlov IM. Perineural cysts of the spinal nerve roots. *Arch Neuropsych.* 1938;40(6):1067-74. [[Crossref](#)]
2. Nabors MW, Pait TG, Byrd EB, Karim NO, Davis DO, Kobrine AI, et al. Updated assessment and current classification of spinal meningeal cysts. *J Neurosurg.* 1988;68(3):366-77. [[Crossref](#)] [[PubMed](#)]
3. Paulsen RD, Call GA, Murtagh FR. Prevalence and percutaneous drainage of cysts of the sacral nerve root sheath (Tarlov cysts). *Am J Neuroradiol.* 1994;15(2):293-7; discussion 298-9. [[PubMed](#)]
4. Strully KJ. Meningeal diverticula of sacral nerve roots (perineural cysts). *J Am Med Assoc.* 1956;21;161(12):1147-52. [[Crossref](#)] [[PubMed](#)]
5. Tarlov IM. Spinal perineural and meningeal cysts. *J Neurol Neurosurg Psychiatry.* 1970;33(6):833-43. [[Crossref](#)] [[PubMed](#)] [[PMC](#)]
6. Dimitroulias AP, Stenner RC, Cavanagh PM, Madhavan P, Webb PJ. Multiple bilateral sacral perineural cysts unusually distal to the exit foramina. *Br J Neurosurg.* 2007;21(5):521-2. [[Crossref](#)] [[PubMed](#)]
7. Takatori M, Hirose M, Hosokawa T. Perineural cyst as a rare cause of L5 radiculopathy. *Anesth Analg.* 2008;106(3):1022-3. [[Crossref](#)] [[PubMed](#)]
8. Jain SK, Chopra S, Bagaria H, Mathur PP. Sacral perineural cyst presenting as chronic perineal pain: a case report. *Neurol India.* 2002;50(4):514-5. [[PubMed](#)]
9. Bayrakli F, Kurtuncu M, Karaarslan E, Ozgen S. Perineural cyst presenting like cubital tunnel syndrome. *Eur Spine J.* 2012;21 Suppl 4(Suppl 4):S387-9. [[Crossref](#)] [[PubMed](#)] [[PMC](#)]
10. Joshi VP, Zanwar A, Karande A, Agrawal A. Cervical perineural cyst masquerading as a cervical spinal tumor. *Asian Spine J.* 2014;8(2):202-5. [[Crossref](#)] [[PubMed](#)] [[PMC](#)]
11. Xu J, Sun Y, Huang X, Luan W. Management of symptomatic sacral perineural cysts. *PLoS One.* 2012;7(6):e39958. [[Crossref](#)] [[PubMed](#)] [[PMC](#)]
12. Tsitsopoulos PP, Marklund N, Salci K, Holtz A, Mani M. Management of symptomatic sacral perineural cysts with microsurgery and a vascularized fasciocutaneous flap. *J Spine Surg.* 2018;4(3):602-9. [[Crossref](#)] [[PubMed](#)] [[PMC](#)]
13. Sharma M, SirDeshpande P, Ugiliweneza B, Dietz N, Boakye M. A systematic comparative outcome analysis of surgical versus percutaneous techniques in the management of symptomatic sacral perineural (Tarlov) cysts: a meta-analysis. *J Neurosurg Spine.* 2019;8:1-12. [[Crossref](#)] [[PubMed](#)]
14. Patel MR, Louie W, Rachlin J. Percutaneous fibrin glue therapy of meningeal cysts of the sacral spine. *Am J Roentgenol.* 1997;168(2):367-70. [[Crossref](#)] [[PubMed](#)]
15. Lee J, Kim K, Kim S. Treatment of a symptomatic cervical perineural cyst with ultrasound-guided cervical selective nerve root block: a case report. *Medicine (Baltimore).* 2018;97(37):e12412. [[Crossref](#)] [[PubMed](#)] [[PMC](#)]
16. Zibis AH, Fylos AH, Arvanitis DL. Symptomatic cervical perineural (Tarlov) cyst: a case report. *Hippokratia.* 2015;19(1):76-7. [[PubMed](#)] [[PMC](#)]