

# Ultrasound-Guided Intra-Articular Ozone Injection as a Therapeutic Option for Hip Osteonecrosis

## Kalça Osteonekrozu İçin Bir Tedavi Seçeneği Olarak İntra-Artiküler Ozon Enjeksiyonu

<sup>ID</sup> Mustafa Turgut YILDIZGÖREN<sup>a</sup>, <sup>ID</sup> Hasan OĞUZ<sup>a</sup>

<sup>a</sup>Department of Physical Medicine and Rehabilitation, Fizikon Medical Center, Konya, TURKEY

**ABSTRACT** Hip osteonecrosis is caused by inadequate blood supply leading to the death of osteocytes. Ozone has a positive effect on cell energy, oxygen metabolism, the antioxidant defense system, and microcirculation in tissues. This case report describes a 45-year old male who presented with bilateral hip pain due to osteonecrosis caused by chronic steroid treatment for Hodgkin's lymphoma, and who was treated with intra-articular ozone.

**Keywords:** Intra-articular injections; osteonecrosis; ozone; pain management

**ÖZET** Kalça osteonekrozu, kan akımının yetersizliği nedeniyle osteositlerin kaybına bağlı olarak gelişir. Ozon tedavisi hücre enerjisini, oksijen metabolizmasını, antioksidan sistemi, dokulardaki mikrosirkülasyonu olumlu yönde etkiler. Bu makalede, Hodgkin lenfoma nedeniyle steroid kullanımına bağlı osteonekroz gelişen ve intra-artiküler ozon enjeksiyonu ile tedavi edilen 45 yaşında bir hasta sunulmuştur.

**Anahtar Kelimeler:** İntraartiküler enjeksiyonlar; osteonekroz; ozon; ağrı yönetimi

Osteonecrosis, also known as avascular necrosis, is a disease caused by decreased blood flow to the bones of joints. Trauma, steroid use, alcoholism and hematological diseases are some of the important causes of osteonecrosis.<sup>1</sup> When osteonecrosis is diagnosed early, operative and non-operative treatments have been described with variable success rates.<sup>2</sup> Non-operative treatment options include a variety of medications (nonsteroidal anti-inflammatory drugs, bisphosphonates, anticoagulants, cholesterol-lowering drugs, vasodilators, etc.), physiotherapy methods (exercises, electrical stimulation, extracorporeal shock wave therapy, pulsed electromagnetic therapy) and hyperbaric oxygen therapy.<sup>3</sup> These treatment options have recently been recommended for the prevention of osteonecrosis progression.<sup>1</sup> Rege-

nerative therapies including stem cells, platelet-rich plasma and bioactive molecules also achieve good clinical results for the treatment of osteonecrosis.<sup>4</sup> In this case, a patient with bilateral hip pain due to osteonecrosis caused by long-term steroid usage for Hodgkin's lymphoma was treated with intra-articular ozone. The results show the short-term effect of ozone.

### CASE REPORT

A 45-year old male presented with complaints of bilateral hip pain and walking difficulties for the last year, and nocturnal hip pain. The initial pain assessment was measured as VAS 7 (Visual Analogue Scale). The medical history revealed a 5-year history of Hodgkin's lymphoma and 1 year previously, core

**Correspondence:** Mustafa Turgut YILDIZGÖREN  
Fizikon Medical Center, Department of Physical Medicine and Rehabilitation, Konya, TURKEY/TÜRKİYE  
**E-mail:** fitr.mustafaturgut@hotmail.com



Peer review under responsibility of Journal of Physical Medicine and Rehabilitation Science.

**Received:** 02 Mar 2020 **Received in revised form:** 30 May 2020 **Accepted:** 24 Jun 2020 **Available online:** 28 Sep 2020

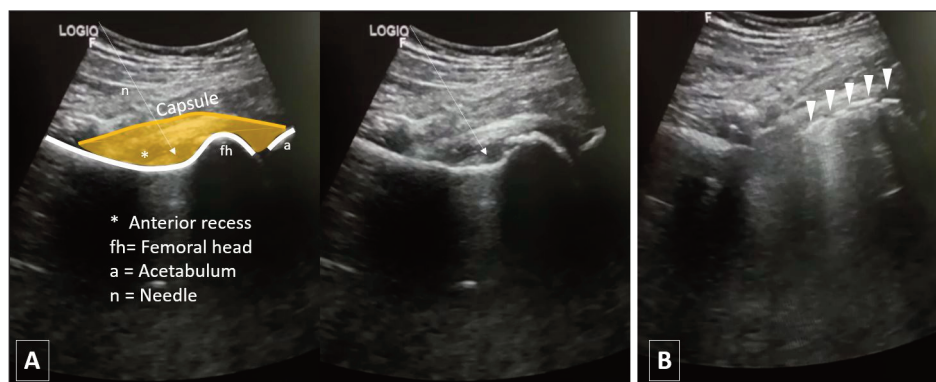
1307-7384 / Copyright © 2020 Turkey Association of Physical Medicine and Rehabilitation Specialist Physicians. Production and hosting by Türkiye Klinikleri.  
This is an open access article under the CC BY-NC-ND license (<https://creativecommons.org/licenses/by-nc-nd/4.0/>).

decompression surgery had been applied to the hips due to osteonecrosis after chronic usage of corticosteroid treatment. Physical examination showed reduced range of passive and active motion of both hips. The patient was limited in climbing stairs (up and down) and required support, in dressing (putting on socks) and in walking which he could only manage successfully for 100 meters limping. With the consideration of osteonecrosis, bilateral plain radiographs and magnetic resonance imaging (MRI) of the hips were obtained. The patient had already received medical treatment for the hip pain (tramadol, paracetamol, nonsteroidal anti-inflammatory drugs, etc). Physical therapy agents (superficial and deep heating agents or laser therapy) were contraindicated due to the previous Hodgkin's lymphoma. Fifteen sessions of electrical stimulation therapy and progressive resistive exercises were given to strength the hip muscles. The patient was also treated with a cycle of 5 ozone therapy sessions at weekly intervals (15 ml ozone at a concentration of 15 µg/ml, 20 µg/ml, 25 µg/ml, 25 µg/ml, and 25 µg/ml, consecutively). The injections were performed under ultrasound guidance (Figure 1). At the end of the treatment, the hip pain had decreased (measured as VAS=2), and walking distance without pain improved up to 1000 meters. A mild burning sensation was reported in the site of injection. No serious adverse effects were observed during the treatment. To improve function, reduce pain and delay joint replacement, intra-articular ozone injections were also planned to be applied for a year at monthly intervals.

## DISCUSSION

Ozone therapy is used for the treatment of a wide range of diseases and seems to be promising in cases of tissue ischemia.<sup>5</sup> Ozone has a positive effect on cell energy, oxygen metabolism, the antioxidant defense system, and microcirculation in tissues. According to these mechanisms of action, it has been hypothesized that ozone therapy could be useful in the tissue repair process.<sup>6</sup> There is a limited number of clinical studies in literature about the effectiveness of ozone in the management of musculoskeletal diseases.<sup>7</sup> The common view in these previous studies is that local ozone therapy has positive results in the regenerative process.<sup>6-8</sup> It is mainly recommended for patients with low back pain, osteoarthritic pain (knee, hip, shoulder, etc.), inflammatory diseases and to deal with symptoms of the diabetic foot.<sup>9</sup>

Ozone is one of the most powerful oxidizing agents, and even a small ozone dose can trigger several useful biochemical mechanisms and reactivate the antioxidant system. The effects of ozone are dose-dependent, so to be able to obtain a stimulating or suppressing effect, the dose used varies according to the oxidative load and antioxidant capacity of the tissue to which it is to be applied.<sup>8</sup> The “therapeutic window” for ozone has been stated to be 10-80 µg/ml (gamma).<sup>10</sup> In applications with doses below the necessary dose, a response cannot be obtained and in unnecessarily high doses, since the antioxidant capacity is exceeded, carbohydrates, enzymes, DNA, and



**FIGURE 1:** Ultrasound-guided ozone injection to the hip joint. (A) Ultrasonographic view showing effusion in the hip joint anterior recess (\*) under the anterior joint capsule (yellow). (B) Distribution of the ozone under the joint capsule (arrowheads)

RNA might be affected by the reactions, as when high concentration ozone is applied locally or systemically, it has anti-bactericidal and anti-virucidal effects.<sup>11</sup> The activation dose of the antioxidant system is 1-30 µg/ml (gamma), regulation dose is 30-50 µg/ml (gamma) and suppression dose is 50-100 µg/ml (gamma). If the doses are too high, cells are extensively damaged and the antioxidant response is suppressed.<sup>12</sup>

In the treatment of inflammatory and degenerative diseases related to the musculoskeletal system, there has been an increase in recent years in the use of local ozone injections which activate the anti-inflammatory and anti-oxidative capacity.<sup>5</sup> Although complete consensus has not been achieved in ozone concentrations and doses, it is applied to the hip joint as 10-15 cc of an oxygen-ozone mixture at a concentration of 15-25 µg/mL at weekly intervals.<sup>13</sup> In the current case, the treatment was initiated with analgesic and anti-inflammatory doses of ozone for pain and joint effusion caused by osteonecrosis.

Ozone therapy is used to alleviate hip pain due to functional overload, pain caused by primary or secondary coxarthrosis, bursitis and tendinitis.<sup>7</sup> Ozone therapy is effective in hip osteonecrosis, which is a condition in which conventional medical approaches are not very effective and the risk of hip surgery is high.<sup>14</sup> Ozone therapy may also help to delay the need

for hip arthroplasty. In the current case, stem-cell therapy, platelet-rich plasma and bioactive molecules were not recommended due to the history of malignancy. A series of local ozone injections were applied into the hip joint using ultrasound. This case has demonstrated the safety and efficacy of ozone therapy when administered in small doses at weekly intervals.

In conclusion, the weekly administration of intra-articular ozone for 5 weeks reduced the pain associated with osteonecrosis and enhanced the pain-free walking distance. From the outcomes of this report, ozone may be considered as an effective adjunctive treatment option for appropriate patients who suffer from hip pain due to osteonecrosis.

#### Source of Finance

*During this study, no financial or spiritual support was received neither from any pharmaceutical company that has a direct connection with the research subject, nor from a company that provides or produces medical instruments and materials which may negatively affect the evaluation process of this study.*

#### Conflict of Interest

*No conflicts of interest between the authors and / or family members of the scientific and medical committee members or members of the potential conflicts of interest, counseling, expertise, working conditions, share holding and similar situations in any firm.*

## REFERENCES

- Banerjee S, Issa K, Pivec R, Kapadia BH, Khanuja HS, Mont MA, et al. Osteonecrosis of the hip: treatment options and outcomes. *Orthop Clin North Am.* 2013;44(4):463-76. [[Crossref](#)] [[PubMed](#)]
- Tripathy SK, Goyal T, Sen RK. Management of femoral head osteonecrosis: current concepts. *Indian J Orthop.* 2015;49(1):28-45. [[Crossref](#)] [[PubMed](#)] [[PMC](#)]
- Gianakos AL, Moya-Angeler J, Duggal S, Zambrana L, Fields KG, Mintz DN, et al. The efficacy of bisphosphonates with core decompression and mesenchymal stem cells compared with bisphosphonates alone in the treatment of osteonecrosis of the hip: a retrospective study. *HSS J.* 2016;12(2):137-44. [[Crossref](#)] [[PubMed](#)] [[PMC](#)]
- Andriolo L, Merli G, Tobar C, Altamura SA, Kon E, Filardo G, et al. Regenerative therapies increase survivorship of avascular necrosis of the femoral head: a systematic review and meta-analysis. *Int Orthop.* 2018;42(7):1689-704. [[Crossref](#)] [[PubMed](#)]
- Benvenuti P. Oxygen-ozone treatment of the knee, shoulder and hip: a personal experience. *Rivista Italiana di Ossigeno-Ozonoterapia* 2006;5(2):135-44.
- Kizilkaya V, Uruc V, Levent A, Kanat O, Yildizgoren MT, Dogramaci Y, et al. Effectiveness of ozone therapy on tendon healing: an experimental study in generated achilles tendon injury model in rats. *Journal of Hard Tissue Biology.* 2018;27(4):309-14. [[Crossref](#)]
- Seyam O, Smith NL, Reid I, Gandhi J, Jiang W, Khan SA, et al. Clinical utility of ozone therapy for musculoskeletal disorders. *Med Gas Res.* 2018;25;8(3):103-10. [[Crossref](#)] [[PubMed](#)] [[PMC](#)]
- Re L, Mawsouf MN, Menéndez S, León OS, Sánchez GM, Hernández F. Ozone therapy: clinical and basic evidence of its therapeutic potential. *Arch Med Res.* 2008;39(1):17-26. [[Crossref](#)] [[PubMed](#)]
- Braidy N, Izadi M, Sureda A, Jonaidi-Jafari N, Banki A, Nabavi SF, et al. Therapeutic relevance of ozone therapy in degenerative diseases: focus on diabetes and spinal pain. *J Cell Physiol.* 2018;233(4):2705-14. [[Crossref](#)] [[PubMed](#)]

10. Sagai M, Bocci V. Mechanisms of action involved in ozone therapy: is healing induced via a mild oxidative stress? *Med Gas Res.* 2011;20;1:29. [[Crossref](#)] [[PubMed](#)] [[PMC](#)]
11. Bozbas GT, Sendur OF. New therapeutic approach in rheumatoid arthritis: ozone. *Int J Physiatry.* 2016;2(1):007. [[Crossref](#)]
12. Bocci V, Zanardi I, Travagli V. Ozone: a new therapeutic agent in vascular diseases. *Am J Cardiovasc Drugs.* 2011;11(2):73-82. [[Crossref](#)] [[PubMed](#)]
13. Diracoglu Demirhan. [Ozone-oxygen therapies in musculoskeletal diseases]. *Turk J Phys Med Rehab.* 2016;62(2):183-91.
14. Sen RK. Management of avascular necrosis of femoral head at pre-collapse stage. *Indian J Orthop.* 2009;43(1):6-16. [[Crossref](#)] [[PubMed](#)] [[PMC](#)]