

# The Effectiveness of Three-Dimensional Glasses in the Visual Field Defect in Patients with Traumatic Brain Injury: A Novel Therapy (TAMKAN's Technique)

## Travmatik Beyin Hasarlı Hastalarda Görme Alanı Defektinde Üç Boyutlu Gözlüğün Etkinliği: Yeni Bir Tedavi (TAMKAN Tekniği)

Arif Uğur TAMKAN<sup>a</sup>,  
Ebru KARACA UMay<sup>a</sup>

<sup>a</sup>Clinic of Physical Medicine and Rehabilitation,  
University of Health Sciences  
Ankara Dışkapı Yıldırım Beyazıt Training and Research Hospital,  
Ankara, TURKEY

Received: 11 Nov 2018  
Received in revised form: 27 Nov 2018  
Accepted: 24 Dec 2018  
Available online: 27 Feb 2019

Correspondence:  
Ebru KARACA UMay  
University of Health Sciences  
Ankara Dışkapı Yıldırım Beyazıt Training and Research Hospital,  
Clinic of Physical Medicine and Rehabilitation, Ankara,  
TURKEY/TÜRKİYE  
ebrumay@gmail.com

**ABSTRACT** Traumatic brain injury (TBI) is a major cause of morbidity and mortality. The effects of TBI are not only restricted to cognitive and physical problems, but also a high rate of vision problems occur. Although a number of comparative studies have been carried out, there is still no consensus on an effective method to treat TBI-related visual field loss. We presented effectiveness of three-dimensional (3D) glasses and computer-based attention treatment which is used as a novel treatment method in two patients with visual field defect and severe TBI. This novel treatment method has yielded significant changes in visual field defect.

**Keywords:** Traumatic brain injury; visual field defect; visual therapy; three-dimensional glasses

**ÖZET** Travmatik beyin hasarı (TBH), önemli bir morbidite ve mortalite nedenidir. Travmatik beyin hasarının etkileri sadece bilişsel ve fiziksel problemlerle sınırlı değildir, aynı zamanda yüksek oranda görme problemleri de oluşur. Literatürde karşılaştırmalı çalışmalar yapılmış olmasına rağmen, TBI'ya bağlı görme alanı kaybını tedavi eden etkili yöntem konusunda hâlâ bir fikir birliği bulunmamaktadır. Görme alanı defekti ve şiddetli TBH olan iki hastada yeni bir tedavi yöntemi olarak kullanılan üç boyutlu (3D) gözlük ve bilgisayar tabanlı dikkat tedavisinin etkinliğini bu çalışmada sunduk. İki hastada bu yeni tedavi yöntemi ile görme alanı defektinde önemli değişiklikler elde edilmiştir.

**Anahtar Kelimeler:** Travmatik beyin hasarı; görme alanı defekti; görme tedavisi; üç boyutlu gözlük

Traumatic brain injury (TBI) is a major cause of morbidity and mortality. It is associated with long-term neurophysiological symptoms even in mild form. The effects of TBI are not only restricted to cognitive and physical problems, but also a high rate of vision problems occur.<sup>1</sup> A wide range of visual complaints might follow TBI. Moreover, up to 97% of TBI patients have visual problems including photophobia, double vision, blurred vision and, loss of vision and visual processing.<sup>2</sup>

Plasticity is the brain's ability to reorganize itself by forming new neural connections during development and after injury or disease. This process starts as soon as one hour following diminished input to a portion of the somatomotor cortex and may take weeks or years to complete. Recent research has also shown that visual therapy can evoke cortical activity changes in the brain.<sup>3</sup> Although a number of comparative studies have

been carried out, there is still no consensus on an effective method to treat TBI-related visual field loss.<sup>4,5</sup>

We presented three-dimensional (3D) glasses and computer-based attention treatment which is used as a new treatment method in two patients with visual field defect and severe TBI (Written consent was obtained from patients and their relatives).

## CASE REPORTS

A 16-year-old girl and a 56-year-old man were admitted to our clinic due to the symptoms including bumping into objects and low vision. The girl had a TBI due to traffic accident 4 years ago. At that time the computed tomography (CT) of the brain revealed parenchymal hemorrhage with diffuse axonal damage in bilateral parietal gray matter, left thalamus and cerebellum. The male patient had TBI due to gunshot wounds 3 years ago. At that time the CT of the brain revealed bilateral temporal and parietal hemorrhage with diffuse axonal damage and cranial bone fragments. No additional trauma was detected in the eyes and face of the patients. Their injuries resulted in severe cognitive, perceptual and language deficiencies and quadriparesis and also Glasgow Coma Scale (GCS) score was 5-7. She began to walk independently after rehabilitation therapy for

8 months. He began to walk with one person aided after rehabilitation therapy for 10 months. Both patients made good progress in regaining cognitive abilities during rehabilitation, but low vision and bumping into object persisted. There was no medication known to affect attention, as well as there was no reported an unremarkable medical/ocular history before accident.

While the duration of the girl's sustaining visual attention was approximately 15 minutes, the man had 5 minutes. Their gross oculomotor examination revealed no restriction, extraocular movements and pupil reflexes were normal. Visual acuity was evaluated by Snellen chart and visual field was evaluated with automated static and kinetic perimetry before and after therapy. There was no visuo-spatial neglect which was evaluated by Rehacom program. Visual acuity of the patients were 20/20 and accommodation was sufficient in bilateral eyes. But on perimetry examination at baseline, their defect of entire visual field is so high than normal values both in left and right eyes (Figure 1 and Figure 2).

The girl's and man's visual field defect was markedly improved 4 and 14 months, respectively after the novel therapy. Also, the duration of the ability to sustain visual attention increased to 60 and 45 minutes, respectively.

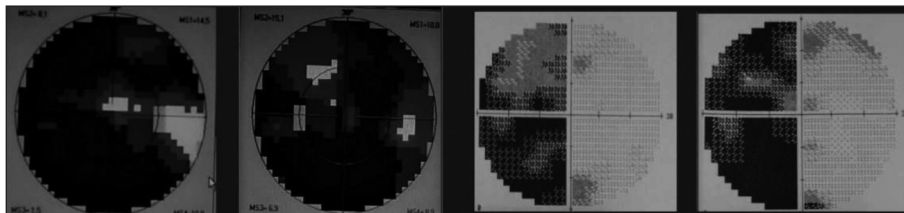


FIGURE 1: Case 1: Perimetric images in right and left eyes before and after therapy, respectively.




FIGURE 2: Case 2: Perimetric images in right and left eyes before and after therapy, respectively.

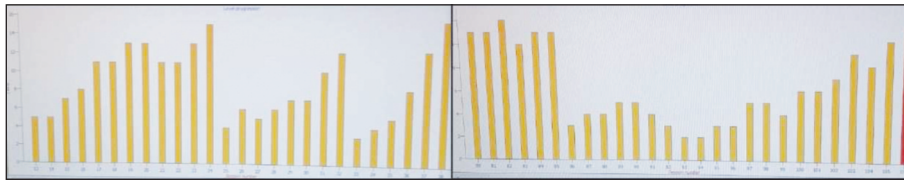


FIGURE 3: Level progression in vigilance for case 1 and 2 by Rehacom program, respectively.

## NOVEL THERAPY METHOD

At the first step of the treatment, a computer-based cognitive rehabilitation program (Rehacom, Hasomed, Germany) was performed for 45 minutes (with a 15 minutes break) a week while bilateral eyes were open.<sup>6</sup> The Rehacom remediation software studied tasks targeting a specific component of attention (alertness, vigilance, divided and selective attention, concentration, responsiveness, reaction behavior and visuo-spatial attention). Progression levels of training at the last sessions are shown in Figure 3.

Afterwards, photos and videos which contained three-dimensional (3D) images were shown to the patients who wore 3D glasses that occurs a red colour transparent film for the left eye and a blue colour transparent film for the right eye. This therapy was performed 60 minutes a day, 5 days a week for 4 months.

## DISCUSSION

Traumatic brain injury (TBI) causes visual disorders including both damaged direct visual pathways and non-visual problems such as lack of attention and concentration. Visual problems of TBI include disorders on visual pathway such as reduced visual acuity, visual fields defect, and oculomotor dysfunction.<sup>7</sup> Non-visual such as inattention, poor concentration and response inconsistency also occur. As the severity of TBI increases, both direct and indirect problems increase. Both of our patients were in the severe stage according to the GCS and had visual field defects due to the extent of cortical involvement rather than a specific cranial nerve involvement. Although the patients' visual acuity was complete, there was a lack of concentration and attention. Although the patients had reported that the most common visual

problem was ocular motility defect (mild findings), visual field defect was reported to be typical for TBI, especially in moderate and severe cases.<sup>1,2</sup> The severe TBI led to a serious loss of visual field in our patients.

There are many studies on the effectiveness of visual rehabilitation in TBI including compensatory, adaptive and restorative strategies and their combinations. Among these strategies currently used to address functional deficits related to various visual dysfunctions and losses (especially for ocular motility defect) are prisms, mirrors, driving simulators, visuospatial training and techniques to improve scanning and perception, as well as brain plasticity and medications.<sup>8</sup> However, the efficacy of these treatments can be affected by many other factors, such as the severity of the initial injury, associated physical injuries, medications and current cognitive disability, especially in severe TBI.

In our patients, there was also a lack of attention and concentration, and a cognitive computer-assisted treatment program was added to the direct treatment that was used for the eye. The program (Rehacom) is a method which uses the visual stimuli to increase and maintain the attention. Studies have reported that repeated stimulation synchronizes neuronal firing in the same areas, and, as this synchronization requires attentional activation, it leads to synaptic plasticity.<sup>4,7</sup> We think that 3D vision rehabilitation combined with this treatment increases this plasticity in our study. Perimetry evaluations made at the end of the study support these results.

There are several studies in the treatment of vision with colored lenses and glasses. Studies have shown that the use of blue lenses is effective in accommodation and ocular motility disorders. In addi-

tion, colored filters have been shown to be effective in children with reading difficulties to reduce eye-strain and increase clarity.<sup>9-11</sup> As a result of these studies; in response to visual stimulus, the imbalance in cortical stimulation has been reported to be regulated by colored (blue) lenses.

No studies are available in literature investigating the use of 3D glasses made of red and blue colored films with 3D photographs and videos in visual rehabilitation.

The 3D visual phenomenon is generated by the parallax effect, which includes both binocular parallax and motion parallax. Binocular parallax is due to the different perspectives of the eyes, resulting in slightly different image messages being received by the left and right eyes. The two received images are combined in the brain to synthesize the stereoscopic effect.<sup>11</sup> This supports the theory that residual neurons within the damaged tissue may be reactivated (minimal residual structure). As reported in the literature, repeated practice strengthens synaptic connections with residual tissue and improves visual function in the blind visual field.<sup>7</sup>

We believe that these good results in our patients indicate that the effect of 3D glasses and image treatment in the brain is much more than the regulation of cortical stimulation.

## LIMITATIONS

This paper presents the results of a preliminary study. Randomized controlled studies are needed to support our results. In addition, we could not use an imaging method such as functional magnetic resonance imaging, which is a limitation of our study.

## CONCLUSION

We consider that this paper indicates that the visual pathway of human has a certain resilience and sufficient plasticity to be able to reorganize itself after brain damage. The residual structures can be reactivated by means of repeated visual stimulation combined attention rehabilitation by using 3D glasses. This method can be appropriate for reactivating injured tissue and/or improving visual performance in everyday life.

## REFERENCES

- Ventura RE, Balcer LJ, Galetta SL. The neuro-ophthalmology of head trauma. *Lancet Neurol.* 2014;13:1006-16. [[Crossref](#)]
- Goodrich GL, Flyg HM, Kirby JE, et al. Mechanisms of TBI and visual consequences in military and veteran populations. *Optom Vis Sci.* 2013;90:105-12. [[Crossref](#)]
- Waldorf R. Treatment of traumatic brain injury-induced oculomotor and binocular vision dysfunctions with vision therapy. *Optom Vis Perf.* 2015;3:324-30.
- Matteo BM, Viganò B, Cerri CG, et al. Visual field restorative rehabilitation after brain injury. *J Vis.* 2016;16:11. [[Crossref](#)]
- Dundon NM, Bertini C, Ládavas E, et al. Visual rehabilitation: visual scanning, multisensory stimulation and vision restoration trainings. *Front Behav Neurosci.* 2015;9:192. [[Crossref](#)]
- Pantzartzidou A, Dionyssiotis Y, Stefan E, et al. Rehacom software application is effective in cognitive rehabilitation of patients with brain injuries. *Phy Med Rehabil Res.* 2017;2:1-4. [[Crossref](#)]
- Ciuffreda KJ, Ludlam DL, Kapoor N. Clinical oculomotor training in traumatic brain injury. *Optom Vis Dev.* 2009;40:16-23.
- Cockerham GC, Goodrich GL, Weichel ED, et al. Eye and visual function in traumatic brain injury. *J Rehabil Res Dev.* 2009;46:811-8. [[Crossref](#)]
- Yu HC, Tsai XH, Luo AC, et al. Study of three-dimensional image brightness loss in stereoscopy. *Appl Sci.* 2015;5:926-41. [[Crossref](#)]
- Willeford KT, Fimreite V, Ciuffreda KJ. The effect of spectral filters on VEP and alpha-wave responses. *J Optom.* 2016;9:110-7. [[Crossref](#)]
- Raz N, Levin N. Neuro-visual rehabilitation. *J Neurol.* 2017;264:1051-8. [[Crossref](#)]