

# Pseudoarthrosis of Cervical Rib and 1<sup>st</sup> Rib Exocytosis in a Patient Presenting with a Supraclavicular Mass: Case Report

## Supraklaviküler Kitle ile Başvuran Hastada Servikal Kostanın 1. Kosta Egzozitozu ile Psödoartrozu

Rabia TERZİ,<sup>a</sup>  
Tülay ÖZER<sup>b</sup>

Clinics of  
<sup>a</sup>Physical Medicine and Rehabilitation,  
<sup>b</sup>Radiology,  
Derince Training and Research Hospital,  
Kocaeli

Geliş Tarihi/Received: 17.12.2015  
Kabul Tarihi/Accepted: 04.01.2016

Yazışma Adresi/Correspondence:  
Rabia TERZİ  
Derince Training and Research Hospital,  
Clinic of Physical Medicine and  
Rehabilitation, Kocaeli,  
TÜRKİYE/TURKEY  
drrabia1@yahoo.com

**ABSTRACT** Cervical rib refers to the presence of an additional costa at the level of the seventh vertebra. Its incidence is 0.2–8 percent and is seen bilaterally in half of the cases. Fusion, bone-bridge or fibrous bands between the cervical and first costa are frequently. However, pseudoarthrosis of the cervical rib with the first rib is reported quite rarely in the literature. In the present case, pseudoarthrosis was present between the cervical rib and the exocytosis, extending from the first rib.

**Key Words:** Pseudoarthrosis; supraclavicular mass; rib

**ÖZET** Servikal kosta servikal 7.vertebra düzeyinde aksesuar ya da fazladan kosta olması olarak bilinir. Toplumda %0,2-8 oranında rastlanmaktadır. Vakaların yarısında bilateral olarak görülmektedir. Servikal kosta ile 1. kosta arasında füzyon, kemik köprü ya da fibroz bantlar sıklıkla saptanmaktadır. Servikal kostanın 1. kosta ile psödoartrozu literatürde oldukça nadir olarak bildirilmiştir. Bu yazıda supraklaviküler kitle ile başvuran hastada servikal kostanın 1. kaburga egzozitozu ile psödoartrozu saptanmış bir olgu sunulmuştur.

**Anahtar Kelimeler:** Psödoartrozis; supraklaviküler kitle; kosta

J PMR Sci 2016;19(3):216-8

Cervical rib refers to the presence of an additional rib at the level of the seventh vertebra. Its incidence is 0.2-8 percent and is seen bilaterally in half of the cases.<sup>1</sup> A differential diagnosis from the long transverse process of the seventh cervical vertebra is needed. It is generally asymptomatic, and is seen incidentally in cervical vertebral graphies. Clinically, it may lead to thoracic outlet syndrome as a result of pressure on the brachial plexus or subclavian vessels. Upon physical examination, it may feel like a mass during deep palpation of the supraclavicular region.<sup>2,3</sup> Although occurring only rarely, pseudoarthrosis of the cervical rib with the first rib has been reported in literature.<sup>4,5</sup> This report documents a case that presented with a supraclavicular mass, and who was diagnosed with exocytosis of the first rib and pseudoarthrosis.

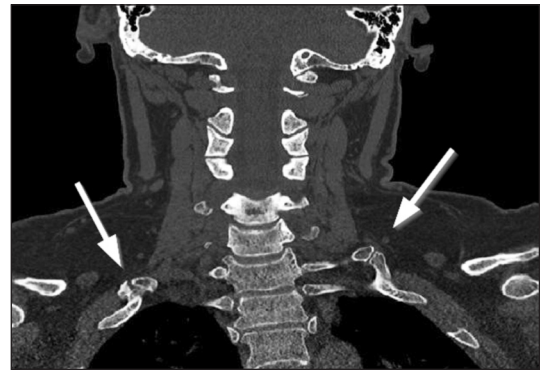## CASE REPORT

A 42-year-old female patient presented with a neck pain for the previous month and swelling in the left supraclavicular region that she noticed two weeks earlier. She stated no history of trauma. Upon physical examination, the range of motion of the cervical joint was free in all directions, and lateral flexion in both directions was minimally painful. She had a paravertebral muscle spasm. A trigger point was present in the fibers of the left upper trapezius muscle, and a hard and immobile mass was felt during deep palpation of the left supraclavicular region. There were no warmth, redness or color changes in the supraclavicular region. Vascular and neurological examinations of both extremities were normal, as were the laboratory test results of the patient. A bilateral cervical rib was noted in the anteroposterior cervical vertebral following an X-ray of the case. The cervical rib was seen in 3D computed tomography (CT) imaging to have developed pseudoarthrosis with the first rib on the right side, while on the left side, pseudoarthrosis was detected between the cervical rib and the exocytosis extending from the first rib (Figures 1, 2). Diclofenac was administered for the pain in a dose of 50 mg twice daily, and local injection therapy was applied to the trigger point. The pain complaint of the patient regressed, and a follow-up plan was made.

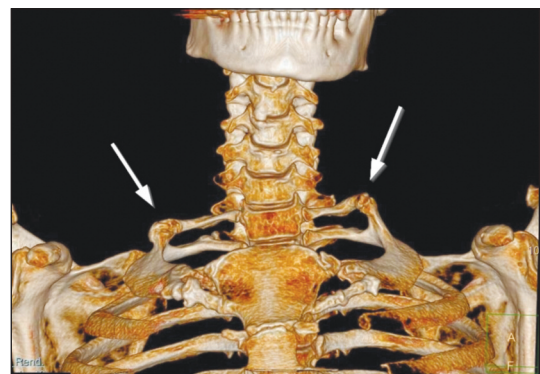
## DISCUSSION

Fusion, bone-bridge or fibrous bands between the cervical and first rib are frequently encountered during surgical operations to treat symptomatic cases of cervical rib; however, pseudoarthrosis of the cervical rib with the first rib is reported quite rarely in the literature.<sup>4-6</sup> In the present case, pseudoarthrosis was present between the cervical rib and the exocytosis, extending from the first rib. To the best of our knowledge, the presence of pseudoarthrosis between the cervical rib and an exocytosis extending from the first rib, as in our case, has only been reported only once before in literature.<sup>7</sup>

Dixit et al. reported on a case with the development of total occlusion in the subclavian vein as



**FIGURE 1:** Coronal tomography sections reveal pseudoarthrosis between the cervical rib and the extension of the first rib on the left side. The right cervical rib forms a direct pseudoarthrosis with the right first rib (arrows).



**FIGURE 2:** In 3D tomography imaging, the pseudojoint relations formed by the bilateral cervical rib with the first rib can be seen in more detail.

a result of pseudoarthrosis of the bilateral cervical rib and the first rib.<sup>4</sup> No abnormal findings were evident in a physical examination of the present case, aside from the supraclavicular swelling and neck pain. Similarly, Jeong et al. detected swelling in the neck in two out of three cases.<sup>8</sup> In the present case, a swelling in the neck was present that the patient had been aware of for one month. Leong and Karkos reported that supraclavicular swelling due to a cervical rib may occur with weight loss, although no significant weight loss was observed in the present case.<sup>9</sup>

Cervical rib are generally noticeable through cervical or chest X-rays, although multiplanar and 3D tomographies are more valuable for detailed evaluations of anatomic structures. Chandak and Kumar diagnosed the presence of a pseudoarthrosis of the cervical rib and the first rib, and demon-

strated it through a 3D CT, and a 3D CT was also selected in the present case to evaluate the anatomical structures in detail.<sup>5</sup>

The treatment of a cervical rib is planned taking into account the presence and severity of the symptoms, with appropriate surgery or conservative treatment selected accordingly. In the presence of pain, medical treatment with analgesics is selected, while the surgical option to be chosen can be a rib resection in addition to a scalenectomy in

the presence of compression findings.<sup>6</sup> In the present case, conservative treatment was selected, with surgery ruled out, given that the patient had no complaint other than swelling.

In cases with swellings of the supraclavicular neck region, pseudoarthrosis between the cervical rib and exocytosis extending through the first rib, as in the present case, should be considered, for which a 3D CT may be useful in the diagnosis.

## REFERENCES

1. Hines K, Graf E, Liu D, Freischlag JA. The rare case of cervical rib fusion to the second rib. *Ann Vasc Surg* 2014;28(3):742.e5-8.
2. Guttentag AR, Salwen JK. Keep your eyes on the ribs: the spectrum of normal variants and diseases that involve the ribs. *Radiographics* 1999;19(5):1125-42.
3. Dähnert W. Congenital rib anomalies. In: Mitchell C, Miller G, eds. *Radiology Review Manual*. 6th ed. Philadelphia: Lippincott Williams & Wilkins; 2007. p.14-6.
4. Dixit M, Gan M, Nishanimath N, Bhagyalakshmi BV, Sajjan P, Dayal A. Double cervical rib with uncommon presentation. *Indian J Thorac Cardiovasc Surg* 2010;26(1):30-3.
5. Chandak S, Kumar A. Usefulness of 3D CT in Diagnosis of Cervical Rib Presenting as Supraclavicular Swelling of Short Duration. *J Clin Diagn Res* 2014;8(5):RD01-2.
6. Chang KZ, Likes K, Davis K, Demos J, Freischlag JA. The significance of cervical ribs in thoracic outlet syndrome. *J Vasc Surg* 2013;57(3):771-5.
7. Saadi MH. Unilateral cervical rib, with exostosis of the first rib and pseudoarthrosis. *1966;20(2):93.*
8. Jeong MS, Mo JA, Choi IJ, Lee MC. Three Cases of Cervical Rib. *Korean J Otorhinolaryngol-Head Neck Surg* 2011; 54(7):482-5.
9. Leong SC, Karkos PD. A "hard" neck lump. *Singapore Med J* 2009;50(4):e141-2.