

# Regression of Extruded Lumbar Disc Herniation: Report of Five Cases and Review of the Literature

## Ekstrüde Lomber Disk Hernisi Regresyonu: Beş Olgu Sunumu ve Literatür Derlemesi

Hidayet SARI,<sup>a</sup>  
Hamza SUCUOĞLU,<sup>b</sup>  
Murat ULUDAĞ,<sup>a</sup>  
Nurettin İrem ÖRNEK<sup>c</sup>

<sup>a</sup>Department of Physical Medicine and Rehabilitation,  
İstanbul University

<sup>b</sup>Cerrahpaşa Faculty of Medicine,  
<sup>c</sup>Clinic of Physical Medicine and Rehabilitation,

Special Bağcılar Active Medical Center,  
<sup>c</sup>Clinic of Physical Medicine and Rehabilitation,

Special Safir Medical Center, İstanbul

Geliş Tarihi/Received: 03.11.2015

Kabul Tarihi/Accepted: 30.11.2015

Yazışma Adresi/Correspondence:

Hamza SUCUOĞLU  
Special Bağcılar Active Medical Center,  
Clinic of Physical Medicine and Rehabilitation, İstanbul,  
TÜRKİYE/TURKEY  
hamzasucuoglu@mynet.com.tr

**ABSTRACT** Lumbar disc herniation (LDH) is a common condition with a good prognosis in the majority of patients. The initial treatment is conservative and includes continued activity, analgesia, and physical therapy. Regression of herniated discs has been described at different levels and with various clinical presentations, including cervical discogenic radiculopathy and myelopathy, thoracic myelopathy, and lumbar radiculopathy. It has been described that larger herniations on the initial scan tend to show greater reduction. Nonoperative treatment can be considered as an option for the management of patients with lumbar disc herniation, especially patients with large and extruded disc herniation. Many studies and case reports in literature have been reported using of various physical therapy modalities in patients with regressed LDH. In this paper, five patients who experienced large extruded lumbar disc herniations are presented. Each of the herniations regressed with medical treatment and physical therapy, as demonstrated by magnetic resonance imaging, with corresponding remission symptoms.

**Key Words:** Lumbar; disc; herniation; regression; physical therapy; rehabilitation

**ÖZET** Lomber disk hernisi (LDH) hastaların çoğunda prognozu iyi olan ve sık görülen bir durumdur. Başlangıç tedavisi konservatif olup, sürekli aktivite, analjezi ve fizik tedaviyi içermektedir. Herniye disklerin regresyonu servikal radikülopati ve miyelopati, dorsal miyelopati ve lomber radikülopati gibi çeşitli klinik durumlarda ve farklı seviyelerde tarif edilmiştir. Bu çalışmada daha büyük hernilerde gerileme eğiliminin daha fazla olduğu tarif edilmiştir. Özellikle büyük ve ekstrüde lomber disk hernisi olan hastaların tedavisinde konservatif tedavi bir seçenek olarak düşünülebilir. Literatürdeki birçok çalışma ve olgu sunumu, LDH regresyonu olan hastalarda çeşitli fizik tedavi yöntemlerinin kullanıldığını bildirmiştir. Bu makalede, büyük ekstrüde lomber disk hernisi olan beş hasta sunulmuştur. Hernisi olan hastaların her birinin medikal tedavi ve fizik tedavi sonrası disk hernilerindeki gerileme klinik olarak ve manyetik rezonans inceleme ile gösterilmiştir.

**Anahtar Kelimeler:** Lomber; disk; herniasyon; regresyon; fizik tedavi; rehabilitasyon

J PMR Sci 2016;19(3):190-6

Lumbar disc herniation (LDH) is a common condition with a favorable prognosis in the majority of patients. The initial treatment is non-operative and includes continued activity, analgesia, and physical therapy and rehabilitation (PTR). It is widely accepted that conservative treatment often succeeds in improving the neurological symptoms.<sup>1,2</sup> The reduction of conservatively treated LDH has been described since the first report by Lindblom et al. in 1950.<sup>3</sup> The introduction of magnetic resonance

imaging (MRI) has provided more detailed information about disc herniations and their natural history. Regression of herniated discs has been described at different levels and with various clinical presentations, including cervical discogenic radiculopathy and myelopathy, thoracic myelopathy, and lumbar radiculopathy.<sup>4</sup> The evidence that resolution of a LDH occurs strengthens the role of a trial of conservative treatment in the absence of cauda equina syndrome before surgical intervention is undertaken.<sup>2</sup>

We present five patients who experienced the large extruded LDH. Each of the herniations had regressed with medical treatment and physical therapy, as demonstrated by MRI, with corresponding remission symptoms.

## CASE REPORTS

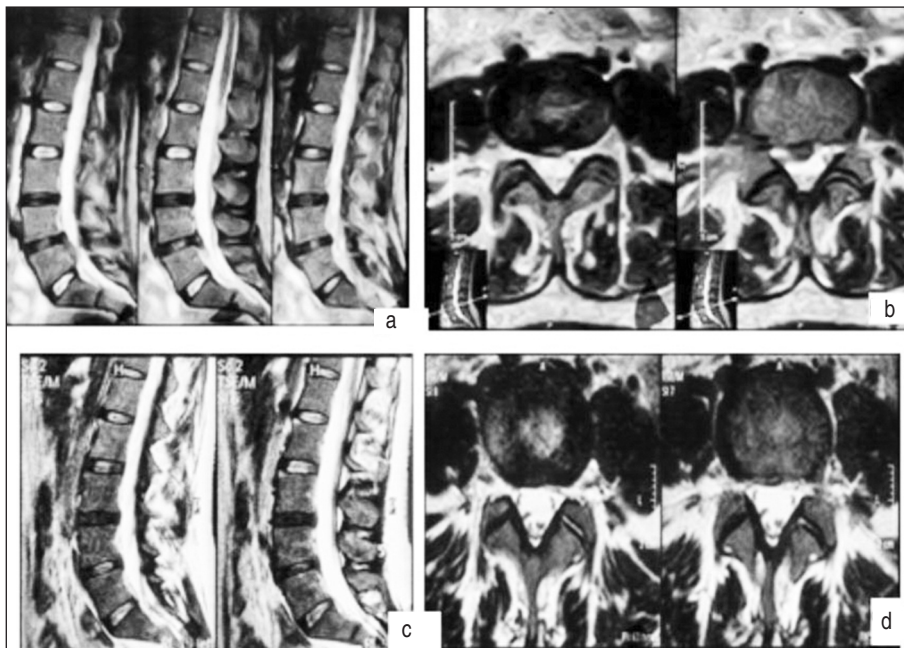
### CASE 1

A 32-year-old female was admitted with low back and right leg pain that started 3 months earlier after carrying a heavy load. Last week, leg pain from the right hip to ankle started. She had paresthesia of the dorsum of the foot and first toe. Lumbar ante-

flexion was limited and the right straight leg-raising (SLR) test was positive at 45°. There was hypoesthesia of the right L5 dermatome and the right ankle and first toe dorsiflexion muscle strength were 4/5. Lumbar MRI showed a caudally migrated, extruded, broad-based disc herniation at the L4-5 level (Figure 1a, b), compressing the right L5 root and dural sac. This was treated with a lumbosacral corset, rest, and 30 sessions of PTR including infrared (IR), transcutaneous electrical nerve stimulation (TENS), ultrasound (US), and electrostimulation (ES) of the tibialis anterior and extensor hallucis longus muscles. After 1 month, her pain and paresthesia improved. Her foot muscle strength returned to normal. Follow-up lumbar MRI showed regression of the extruded disc at the L4-L5 level (Figure 1c, d).

### CASE 2

A 38-year-old male was admitted with low back and right leg pain that started 1 month earlier after carrying a heavy load. On physical examination, his low back movements were limited and painful; the SLR test was positive on the right side at 45°; there was hypoesthesia of the right S1 dermatome



**FIGURE 1:** Sagittal (a) and axial (b) MRI demonstrating a caudally migrated extruded disc at L4-L5 level and compressing the right L5 root; as compared to the sagittal (c) and axial (d) MRI scans of the same patient six months later.

and the right Achilles reflex was absent. The muscle strength in the lower extremities was normal. Lumbar MRI showed broadly extruded disc herniation at the right L5-S1 paramedian level, with right S1 root compression (Figure 2a, b). Initially, he was treated with a lumbosacral corset, rest, and medication. In addition, he underwent 20 sessions of PTR, including IR, TENS, US to lumbar region and lumbar strengthening exercises (LSE). His complaints disappeared and he was able to continue his daily life. The lumbar range of motion was normal and painless. The hypoesthesia of the right S1 dermatome resolved but the Achilles reflex was absent. Follow-up MRI showed no right paramedian extruded disc herniation or S1 root compression (Figure 2c, d).

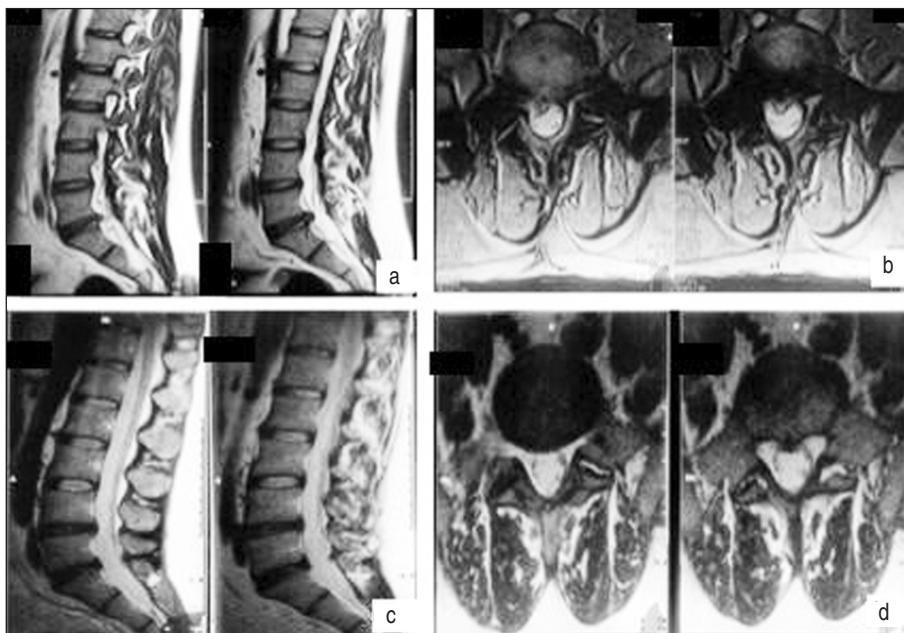
### CASE 3

A 38-year-old male had severe low back pain and left leg pain for 1 year. The pain had increased in the previous month. On physical examination, his low back movements were severely limited and painful. He had an antalgic position, with severe pain on standing and sitting, and difficulty walking. There was no neurological deficit. The SLR test was positive at 45° and the Lasègue test was positive

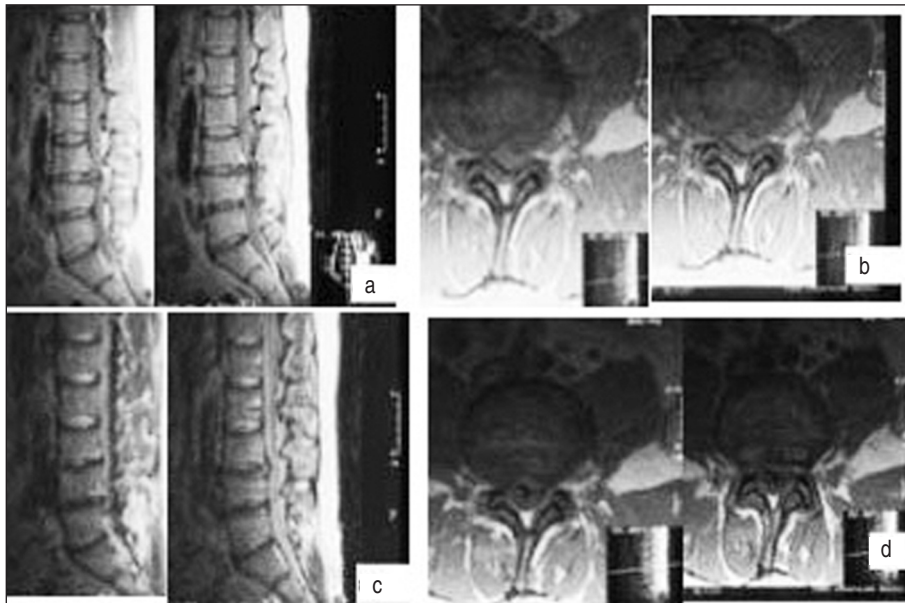
bilaterally. MRI showed L3-L4 central left paramedian disc herniation (Figure 3a, b). His complaints resolved almost completely after 20 sessions of physical therapy, including IR, US, TENS, LSE, and acupuncture treatment. Three months later, the left paramedian extruded herniation at L3-L4 had regressed (Figure 3c, d).

### CASE 4

A 47-year-old male was admitted to our clinic with severe low back pain that began after carrying a heavy load 2 weeks earlier. On physical examination, the lumbar range of motion was limited and was painful at anteflexion. The SLR test at 45° and Valsalva test were positive. There was hypoesthesia of the right L5 dermatome. His right ankle dorsiflexion muscle strength was 2/5. MRI showed right posterolateral extruded herniation and right L5 root compression at the L4-L5 level and median protruded herniation at the L5-S1 level (Figure 4a, b). Severe partial denervation was reported for the muscles innervated by the right L5 root on electromyography (EMG). Because the patient had a foot drop, surgery was indicated. However, because the foot drop developed 2 weeks earlier and he refused surgical treatment, he was treated conserva-



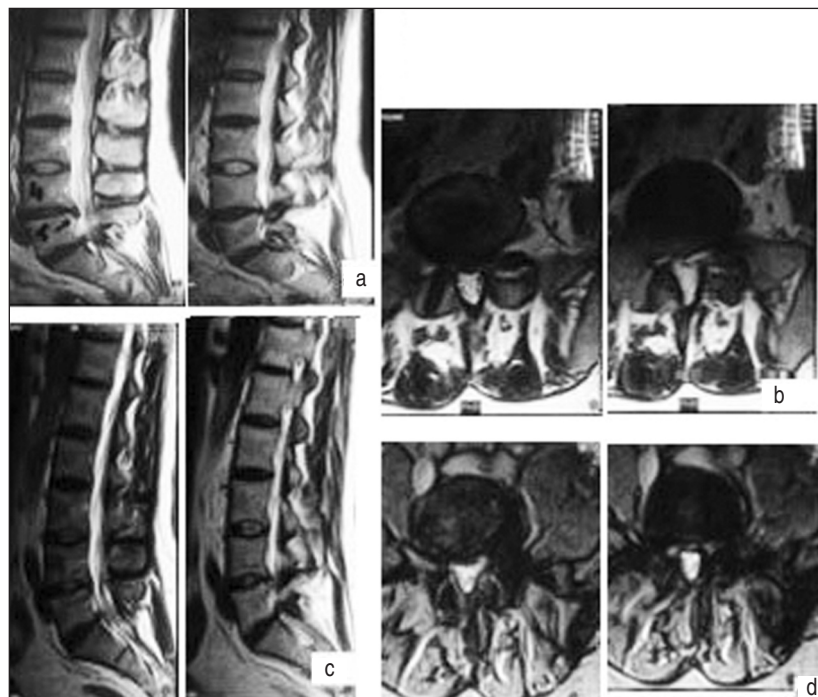
**FIGURE 2:** Sagittal (a) and axial (b) MRI demonstrating a right paramedian extruded disc at L5-S1 level and compressing the right S1 root; as compared to the sagittal (c) and axial (d) MRI scans of the same patient one year later.



**FIGURE 3:** Sagittal (a) and axial (b) MRI demonstrating a left paramedian extruded disc at L3-L4 level; as compared to the sagittal (c) and axial (d) MRI scans of the same patient three months later.

tively with medications, PTR (IR, US, TENS, ES, LSE) and lumbosacral corset. His clinical complaints improved and the neurological deficit diminished. Ankle dorsiflexion muscle strength was

improved to 4/5. Follow-up MRI showed that the right posterolateral extruded herniation at the L4-5 level and protruded disc herniation at the L5-S1 level had regressed (Figure 4c, d).



**FIGURE 4:** Sagittal (a) and axial (b) MRI demonstrating a right posterolateral extruded disc at L4-5 level and protruded disc at L5-S1 level; as compared to the sagittal (c) and axial (d) MRI scans of the same patient fifteen months later.



### CASE 5

A 49-year-old male was admitted to our clinic with low back and left leg pain that had starting 6 months earlier. The physical examination showed flattening of his lumbar lordosis, and tenderness at the left paravertebral muscles and Valleix points. His lumbar movements were limited and painful in anteflexion. The left Achilles reflex had disappeared and there was hypoesthesia of the left S1 dermatome. The SLR test was positive at 40°. Lumbar MRI showed a left posterolateral extruded disc herniation at the L5-S1 level compressing the left L5 root (Figure 5a, b). He was treated with medication, lumbosacral corset, 20 sessions of PTR including IR, US, TENS, and LSE. Within 1 month of the start of conservative treatment, the patient's complaints had resolved. Follow-up MRI showed regression of the extruded disc herniation at the L5-S1 level (Figure 5c, d).

### DISCUSSION

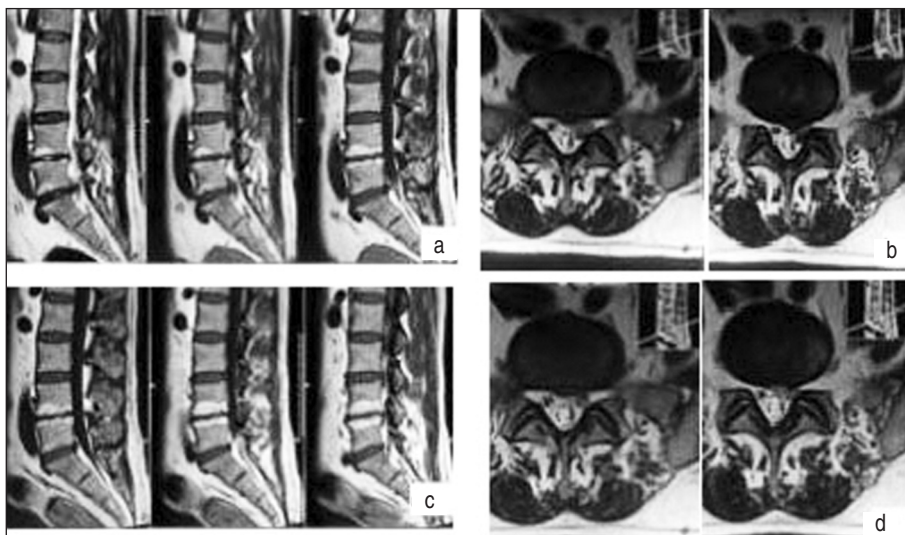
Many researchers report that patients requiring surgery after failing to respond to conservative therapy make up only 2-10% of all cases of LDH.<sup>5</sup> On other hand, the complication or failure rate after lumbar disc surgery ranges from 5 to 10% of cases, while the possibility of resolution is estimated between 70% and 90%. Even anatomical re-

covery ranges between 65% and 70% of cases, the final rate of recovery and recovery post- surgery being similar after a few years.<sup>6</sup> The reductions of lumbar, dorsal and cervical disc herniations have been described numerous times.<sup>6-8</sup> Bozzao et al. reported the natural history of LDH in 69 patients during an average of 11 months by MRI and described that 68% patients showed a reduction of disc herniation.<sup>9</sup> Komori et al. followed up, for an average of 150 days, 77 patients treated nonoperatively and observed a reduction of the herniation in 63.7% of patients.<sup>10</sup> Masui et al. also reported reduction on the 2-year scan was seen in 71.4% of patients, during the following 5 years of observation, LDH decreased in 95% of patients.<sup>11</sup> It has been described that larger herniations on the initial scan tend to show greater reduction.<sup>12,13</sup>

Takada et al. reported that the time taken for regression of the herniated mass by >50 % varied from 3 to 12 months.<sup>14</sup> Keskil et al. reported that totally regressed of four patients with lumbar disc protrusion by varying periods from 10 months to 7 years.<sup>15</sup>

Our five patients with extruded LDH were also regressed by varying periods from 1 month and 15 months (Table 1).

The exact mechanism of disc regression remains unknown. Three main mechanisms are pres-



**FIGURE 5:** Sagittal (a) and axial (b) MRI demonstrating a left posterolateral extruded disc at L5-S1 level, compressing the left L5 root; as compared to the sagittal (c) and axial (d) MRI scans of the same patient two months later.

**TABLE 1:** Characteristics of five patients with extruded lumbar disc herniation.

Case	Age, Gender	Symptom duration (months)	LDH level	PTR methods	Time between initial and control MRI (months)
1	32 F	3	L4-5	IR, US, TENS, ES	6
2	38 M	1	L5-S1	IR, US, TENS, LSE	12
3	38 M	12	L3-4	IR, US, TENS, Acupuncture, LSE	3
4	47 M	0.5	L4-5	IR, US, TENS, LSE, ES	15
5	49 M	6	L5-S1	IR, US, TENS, LSE	2

M: Male; F: Female; LDH: Lumbar disc herniation; MRI: Magnetic resonance imaging; PTR: Physical Therapy and Rehabilitation; IR: Infrared; US: Ultrasound; TENS: Transcutaneous electrical nerve stimulation; ES: Electrostimulation; LSE: Lumbar strengthening exercises.

ent in the literature. The first, the theory of dehydration, states that the herniated disc fragment disappears due to gradual dehydration and shrinkage. The second hypothesis, the theory of resorption, the most experimentally studied one, supports the idea of cartilaginous tissue resorption through enzymatic degradation and phagocytosis as a result of an inflammatory reaction and neovascularization. According to the third explanation, the theory of retraction, the herniated disc retracts back into the intervertebral space. This is the case if the disc protrudes through the annulus fibrosus but at the same time is not separated from it. It is possible, though, that all three proposed mechanisms play a role in the reduction process.<sup>1,4,16,17</sup>

Studies have showed that macrophages play a vital role in both resorption and cytokine signaling to promote endothelial cell proliferation and neovascularization.<sup>18</sup> Individual variations in the expression of various molecules and cytokines also may be found to play a pivotal role in the natural history of intervertebral disc herniations and this may be a target for symptomatic control.<sup>8</sup>

There is no clear correlation between examination findings or pain and disability scores and size of herniated disc on MRI scans. Clinical improvement frequently correlates with radiographic disc regression. However, longitudinal studies of nonsurgically managed patients with documented disc herniations did not show a direct relationship between clinical and radiographic improvement. It appears therefore that symptomatic improvement may occur without significant morphological changes, or that such clinical improvement pre-

cedes the radiographic changes. This discrepancy may be explained by the progressive decrease in pressure exerted by herniated fragments on neighboring neural structures and the gradual improvement of the inflammatory response that accompanies the herniation.<sup>18,19</sup>

Nonsurgical care can be considered as an option for the treatment of patients with lumbar disc herniation, especially patients with large and extruded disc herniation. For neurosurgeons and physiatrists who encounter patients with LDH, it is useful to know that regression can occur in a short period.<sup>16</sup> It is possible that this phenomenon of regressing lumbar disc herniation occurs more frequently. These cases are probably not detected because few patients have MRI examinations after the resolution of their symptoms. It is important to be aware that regression of herniated discs occurs, so that patients can be reassured and the role of conservative treatment can be emphasized.<sup>2</sup>

Many studies and case reports in literature have been reported using of various physical therapy modalities in patients with regressed LDH.<sup>1,4,14,17-21</sup>

Unlu et al. showed that each of the traction, laser, and US therapies results in improvement of clinical assessments, and repeated MRI scans provided evidence of significant morphological regression of herniated discs.<sup>19</sup> They detected significant MRI changes after 3 weeks and therefore they concluded to have the beneficial effects of these treatments on regression of LDH. The thermal (deep heat), mechanical, and biological effects of ultrasound may help inflammation-mediated resorption by reducing pain and edema and acceler-

ate healing in damaged tissue. In addition, these modalities break the pain-spasm-pain cycle by a spasmolytic effect in muscles.

In our case series, the extruded disc herniation was at the L5-S1 level in two patients, L4-5 level in two patients, and L3-4 level in one patient. One patient was a 32-year-old female with extruded disc herniation at L4-5, while the other four patients were men aged 38-49 years (Table 1). All patients were given both pharmacological treatment with nonsteroidal anti-inflammatory drugs, analgesics, and muscle relaxants and physical therapy, including IR, US, and TENS, and exercise. The patients improved both clinically and radiologically with this regimen.

## CONCLUSION

Whatever the size of lumbar disc herniation, conservative treatment will be useful initially in patients with slight or middle neurological symptoms. Regression of disc herniation has been reported spontaneously in many studies. However conservative treatment applications including physical therapy were performed in many of these articles. It is unclear how much the conservative treatments contributed to the regression of the extruded disc herniation or whether it was spontaneous; controlled studies are needed to address this. In addition, MRI is useful for monitoring of regression of herniated disc.

## REFERENCES

- Biribilis TA, Matis GK, Theodoropoulou EN. Spontaneous regression of a lumbar disc herniation: case report. *Med Sci Monit* 2007; 13(10):CS121-3.
- Ushewokunze S, Abbas N, Dardis R, Killeen I. Spontaneously disappearing lumbar disk protrusion. *Br J Gen Pract* 2008;58(554):646-7.
- Lindblom K, Hultqvist G. Absorption of protruded disc tissue. *J Bone Joint Surg Am* 1950;32-A(3):557-60.
- Slavin KV, Raja A, Thornton J, Wagner FC Jr. Spontaneous regression of a large lumbar disc herniation: report of an illustrative case. *Surg Neurol* 2001;56(5):333-7.
- Kobayashi S, Meir A, Kokubo Y, Uchida K, Takeno K, Miyazaki T, et al. Ultrastructural analysis on lumbar disc herniation using surgical specimens: role of neovascularization and macrophages in hernias. *Spine (Phila Pa 1976)* 2009;34(7):655-62.
- Martínez-Quiñones JV, Aso-Escario J, Consolini F, Arregui-Calvo R. Spontaneous regression from intervertebral disc herniation. *Propos of a series of 37 cases. Neurocirugia (Astur)* 2010;21(2):108-17.
- Kobayashi N, Asamoto S, Doi H, Ikeda Y, Matusmoto K. Spontaneous regression of herniated cervical disc. *Spine J* 2003;3(2):171-3.
- Reyentovich A, Abdu WA. Multiple independent, sequential, and spontaneously resolving lumbar intervertebral disc herniations: a case report. *Spine (Phila Pa 1976)* 2002;27(5):549-53.
- Bozzao A, Gallucci M, Masciocchi C, Aprile I, Barile A, Passariello R. Lumbar disk herniation: MR imaging assessment of natural history in patients treated without surgery. *Radiology* 1992;185(1):135-41.
- Komori H, Shinomiya K, Nakai O, Yamaura I, Takeda S, Furuya K. The natural history of herniated nucleus pulposus with radiculopathy. *Spine (Phila Pa 1976)* 1996;21(2):225-9.
- Masui T, Yukawa Y, Nakamura S, Kajino G, Matsubara Y, Kato F, et al. Natural history of patients with lumbar disc herniation observed by magnetic resonance imaging for minimum 7 years. *J Spinal Disord Tech* 2005;18(2):121-6.
- Baldwin NG. Lumbar disc disease: the natural history. *Neurosurg Focus* 2002;13(2):E2.
- Benoist M. The natural history of lumbar disc herniation and radiculopathy. *Joint Bone Spine* 2002;69(2):155-60.
- Takada E, Takahashi M, Shimada K. Natural history of lumbar disc hernia with radicular leg pain: Spontaneous MRI changes of the herniated mass and correlation with clinical outcome. *J Orthop Surg (Hong Kong)* 2001;9(1):1-7.
- Keskil S, Ayberk G, Evliyaoğlu C, Kizartıcı T, Yücel E, Anbarci H. Spontaneous resolution of "protruded" lumbar discs. *Minim Invasive Neurosurg* 2004;47(4):226-9.
- Nozawa S, Nozawa A, Kojima H, Shimizu K. Spontaneous disappearance of lumbar disk herniation within 3 months. *Orthopedics* 2009;32(11):852.
- Gezici AR, Ergün R. Spontaneous regression of a huge subligamentous extruded disc herniation: short report of an illustrative case. *Acta Neurochir (Wien)* 2009;151(10):1299-300.
- Sabuncuoğlu H, Özdoğan S, Timurkaynak E. Spontaneous regression of extruded lumbar disc herniation: report of two illustrative case and review of the literature. *Turk Neurosurg* 2008;18(4):392-6.
- Unlu Z, Tasci S, Tarhan S, Pabuscu Y, Islak S. Comparison of 3 physical therapy modalities for acute pain in lumbar disc herniation measured by clinical evaluation and magnetic resonance imaging. *J Manipulative Physiol Ther* 2008;31(3):191-8.
- Chang CW, Lai PH, Yip CM, Hsu SS. Spontaneous regression of lumbar herniated disc. *J Chin Med Assoc* 2009;72(12):650-3.
- Çitişli V, İbrahimoğlu M. Spontaneous remission of a big subligamentous extruded disc herniation: case report and review of the literature. *Korean J Spine* 2015;12(1):19-21.