

# Complex Regional Pain Syndrome Involved Both Upper and Lower Limbs in a Stroke Patient

## İnmeli Hastada Üst ve Alt Ekstremitte Tutulumu Gösteren Kompleks Bölgesel Ağrı Sendromu

Hüma Bölük, İlkyay Karabay, Gökhan Tuna Öztürk, Canan Polat, Tülay Tiftik, Murat Ersöz

Ankara Physical Medicine and Rehabilitation Training and Research Hospital, Department of Physical Medicine and Rehabilitation, Ankara, Turkey

### ABSTRACT

Complex regional pain syndrome (CRPS) is characterized by pain in a limb in association with sensory, vasomotor, sudomotor, motor and dystrophic changes. Pain is typically leading symptom. CRPS type 1 (much more common) is a disabling problem after stroke and it is frequently reported in plegic upper limb, also known as shoulder-hand syndrome. However, only a small number of patients have CRPS-1 in the lower limb.

In this article a 75 year-old right hemiplegic woman who had ischemic stroke a year ago, complained of pain in extremities, diagnosed as CRPS-1 in both hemiplegic upper and lower extremities presented. After medical and physical therapy her pain was relieved and it affected rehabilitation process positively.

**Keywords:** Complex regional pain syndrome, stroke, lower limb involvement, simultaneous involvement

### ÖZET

Kompleks bölgesel ağrı sendromu (KBAS) ekstremitede ağrı, duyu, vazomotor, sudomotor, motor ve distrofik değişikliklerle karakterizedir. Ağrı tipik, önde gelen semptomdur. KBAS tip 1 (daha sık) inme sonrası dizabiliteye neden olan daha sık plejik üst ekstremitede karşılaşılan, omuz-el sendromu olarak da bilinen bir durumdur. Sadece az sayıda hastada alt ekstremitede görülür.

Bu makalede 75 yaşında 1 yıl önce geçirilen iskemik inme sonucu sağ hemiplejik kalan, ekstremitelerde ağrı şikayeti olup üst ve alt ekstremitede KBAS-1 saptanan kadın hasta sunulmuştur. Medikal ve fizik tedavi sonrası ağrısı gerilemiş ve bu durum rehabilitasyon sürecini olumlu yönde etkilemiştir.

**Anahtar sözcükler:** Kompleks bölgesel ağrı sendromu, inme, alt ekstremitte tutulumu, eş zamanlı tutulum

### Corresponding Author Yazışma Adresi

Hüma Bölük

Ankara Physical Medicine and  
Rehabilitation Training and Research  
Hospital, Department of Physical  
Medicine and Rehabilitation,  
Ankara, Turkey

**E-mail:** humaboluk@gmail.com

**Received/Geliş Tarihi:** 17.10.2015  
**Accepted/Kabul Tarihi:** 11.12.2015

## Introduction

Complex regional pain syndrome (CRPS) is characterized by pain in a limb in association with sensory, vasomotor, sudomotor, motor and dystrophic changes. Pain is typically leading symptom. CRPS can be divided into two types.

Type 1, may arise following nerve lesion. Type 2 has evidence of obvious nerve lesion (1). In some of the

cases, inducing factor may not be identified (2,3). The pathophysiology is still unclear.

CRPS type 1 (much more common) is a disabling problem after stroke and it is frequently reported in plegic upper limb, also known as shoulder-hand syndrome. However, only a small number of patients have CRPS-1 in the lower limb. CRPS negatively effects rehabilitation process, so it is important to diagnose and treat early.

In this case report a 70 year-old right hemiplegic woman who developed CRPS-1 in both right upper and lower limbs simultaneously is presented and discussed with the review of literature.

## Case Report

A 75 year-old female patient with right hemiplegia referred to our inpatient clinic for rehabilitation after ischemic stroke. Her medical history included hypertension and diabetes mellitus. She had a complaint of constant and severe pain of right shoulder and hip and she had no treatment about this complaint. The motor recovery stage of the right upper and right lower limbs were 2 according to Brunnstrom motor recovery scale. She did not have spasticity. On locomotor system examination; her right shoulder was subluxated, dorsum of right hand was edematous and pale in colour, passive range of motion (PROM) of right shoulder was restricted and passive movements of right shoulder, wrist and fingers were painful. PROM of right hip was painful.

Blood tests revealed mildly elevated uric acid level (7 mg/dL) (normal range: 2,6-6 mg/dL) and decreased HDL cholesterol (30mg/dl) (normal range: 40-60 mg/dL), creatin kinase (14U/L) (normal range: 29-168 U/L),

lactat dehydrogenase (119U/L) (normal range: 125-220 U/L) levels. The other parameters were in normal range, including C-reactive protein, liver and kidney functions.

In radiologic examination; patchy osteoporosis of right shoulder and right hip and findings in accordance with CRPS were present. In three-phased bone scintigraphy revealed CRPS involvement of both right upper and lower limbs (Figure 1). With the clinical and scintigraphic findings the patient was diagnosed as CRPS-1 in the upper and lower limbs on hemiplegic side.

After daily administration of transcutaneous electrical nerve stimulation (TENS) to affected limbs and administration of pregabalin which was increased gradually to 300 mg/day dose, the symptoms and signs were diminished gradually within 4 weeks.

## Discussion

CRPS-1 is a disabling and painful problem in stroke patients. Pain is critical for patient to participate in rehabilitation program. Diagnose and treatment have to be done as early as possible. Contribution of glenohumeral subluxation and immobilization to the occurrence of CRPS-1 in hemiplegia had been reported previously (4).

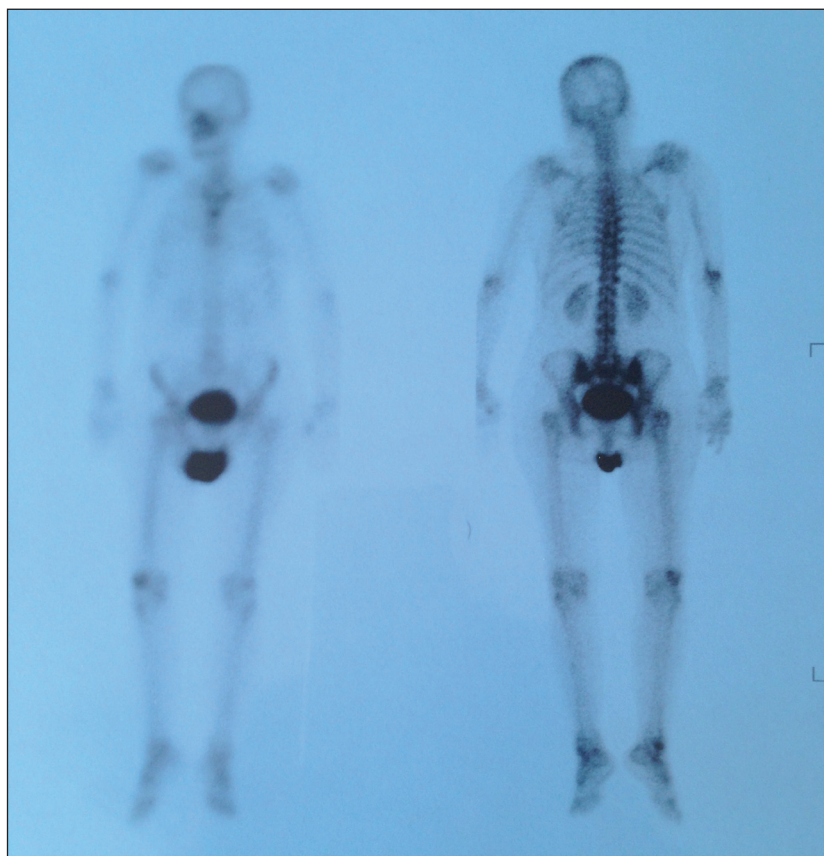


Figure 1. Increased uptake of tc-99m MDP in paretic right upper and lower limb.

Right shoulder of our patient was subluxated inferiorly and she had an immobilization history for a year after stroke. Also it was stated that lower motor recovery stages were associated with CRPS (5). Patient's motor recovery stages were 2 according to brunnstrom motor recovery scale. We believe that these risk factors played role in the development of CRPS-1 in our patient.

CRPS-1 in hemiplegic lower limbs is known to be rare. In a recent report one hemiplegic patient who had CRPS-1 of both left upper and lower extremities have been presented (6). Predisposing factors of CRPS-1 in hemiplegic lower limbs are not defined significantly. Diagnosis of CRPS is based on clinical findings. Imaging techniques can support diagnose and exclude other possible reasons of symptoms. Osteopenia, soft tissue swelling or cortical resorption can be determined in radiographic images. Three phase bone scintigraphy is a more sensitive technique than magnetic resonance imaging (MRI) and radiography (7). In a meta-analysis related to subject, reported that three-phase bone scintigraphy is a sensitive procedure for the early diagnose. Our patient had patchy osteoporosis in both upper and lower extremities and three-phase bone scintigraphy supported the diagnosis.

In CRPS-1 multiple treatment modalities have been described. In our patient, we used transcutaneous electrical nerve stimulation (TENS) and pregabalin to relieve pain. TENS activates specific pain relief mechanisms and it can be used successfully in clinical practice as a supportive treatment (8,9).

Pregabalin is a novel GABA analog, primary mechanism of action involves binding the subunit of voltage-sensitive calcium channels (10). It is an anticonvulsant also used for various neuropathic pain syndromes. We preferred pregabalin as the first choice and it was tolerated well. The patient's pain diminished by increasing the dosage and her participation in rehabilitation process is increased.

In conclusion, in stroke patients with pain in paretic extremities CRPS-1 involvement of lower limb and both upper and lower limbs simultaneously should be kept in mind.

## References

1. McCabe CS, Blake DR. An embarrassment of pain perceptions? Towards an understanding of and explanation for the clinical presentation of CRPS type 1. *Rheumatology (Oxford)* 2008; 47:1612-1616.
2. Wasner G, Schattschneider J, Binder A, Siebrecht D, Maier C, Baron R. Recent trends in understanding and therapy of complex regional pain syndromes. *Anaesthetist* 2003; 52:883-895.
3. Daviet JC, Salle JY, Borie MJ, Munoz M, Rebeyrotte I, Dudognon P. Clinical factors associate with shoulder subluxation in stroke patients. *Ann Readapt Med Phys* 2002; 45:505-509.
4. Aras MD, Gokkaya NK, Comert D, Kaya A, Cakci A. Shoulder pain in hemiplegia: results from a national rehabilitation hospital in Turkey. *Am J Phys Med Rehabil* 2004; 83:713-719.
5. Gokkaya NK, Aras M, Yesiltepe E, Koseoglu F. Reflex sympathetic dystrophy in hemiplegia. *Int J Rehabil Res* 2006; 29:275-279.
6. Unlü Şakaci I, Ersöz M, Tunç H, Yilmaz S, Akkuş S. Simultaneous complex regional pain syndrome of the upper and lower limb in a stroke patient. *Eur J Phys Rehabil Med* 2012; 48:155-161.
7. Cappello ZJ, Kasdan ML, Louis DS. Meta-analysis of imaging techniques for the diagnosis of complex regional pain syndrome type I. *J Hand Surg Am* 2012; 37:288-296.
8. Kesler RW, Saulsbury FT, Miller LT, Rowlingson JC. Reflex sympathetic dystrophy in children: treatment with transcutaneous electric nerve stimulation. *Pediatrics* 1988; 82:728-732.
9. Kılınc M, Livanelioglu A, Yıldırım SA, Tan E. Effects of transcutaneous electrical nerve stimulation in patients with peripheral and central neuropathic pain. *J Rehabil Med* 2014; 46. doi: 10.2340/16501977-1271.
10. Dalal KL, Felix ER, Cardenas DD. Pregabalin for the management of neuropathic pain in spinal cord injury. *Pain Manag* 2013; 3:359-367.