

Sacroiliac Involvement in an End Stage Renal Disease Patient with Secondary Hyperparathyroidism and Familial Mediterranean Fever: Inflammatory or Destructive?

Ailevi Akdeniz Ateşi, Son Dönem Böbrek Hastalığı ve Sekonder Hiperparatiroidizmi Olan Bir Olguda Sakroiliak Eklem Tutulumu: İnflamatuvar mı, Destrüktif mi?

Sibel Mandiroğlu¹, Alper Kırkpantur², Ebru Alemdaroğlu¹

¹Ankara Physical Medicine and Rehabilitation Training and Research Hospital, Department of 2nd Physical Medicine and Rehabilitation, Ankara, Turkey

²RFM Dialysis Center, Department of Nephrology, Ankara, Turkey

ABSTRACT

Sacroiliitis is a rare joint involvement of Familial Mediterranean Fever (FMF). Roentgenographic and pathologic abnormalities of the sacroiliac joint have been previously demonstrated in patients with renal osteodystrophy. We, here, presented a FMF patient on hemodialysis with secondary hyperparathyroidism who developed sacroiliac joint disease during follow-up.

Keywords: Sacroiliitis, Familial Mediterranean Fever, secondary hyperparatiroidism, hemodialysis, rehabilitation

ÖZET

Sakroileit, Ailevi Akdeniz Ateşinde (AAA) nadir görülen bir eklem tutulumudur. Renal osteodistrofide, hem radyolojik hem de patolojik olarak sakroiliak tutulum tanımlanmış bir klinik tablodur. Bu makalede hemodiyalize giren ve sekonder hiperparatiroidisi olan bir FMF hastasında gelişen sakroileiti literatür eşliğinde sunmayı planladık.

Anahtar sözcükler: Sakroileit, Ailevi Akdeniz Ateşi, sekonder hiperparatiroidizm, hemodiyaliz, rehabilitasyon

Corresponding Author Yazışma Adresi

Sibel Mandiroğlu

S.B Ankara Fizik Tedavi ve Rehabilitasyon Eğitim ve Araştırma Hastanesi, 2. Fizik Tedavi ve Rehabilitasyon Kliniği, Ankara, Turkey

E-mail: sblmandir@hotmail.com

Received/Geliş Tarihi: 28.05.2014
Accepted/Kabul Tarihi: 26.11.2014

Introduction

Familial Mediterranean Fever (FMF) is an autosomal recessive disease which predominantly affects people from the Mediterranean basin (1). It is characterized by recurrent and short duration (1-3 days) of fever, and serositis (2). Articular involvement occurs in 70%–75% of patients (3). Sacro-iliitis is a rare presentation in FMF and can be associated with spinal involvement (4).

Abnormalities involving the musculoskeletal system are frequent in patients with chronic renal disease (5). The spectrum of these abnormalities seen on routine radiologic examinations of patients with renal osteodystrophy are the findings seen in secondary hyperparathyroidism (bone resorption, periosteal reaction, and brown tumors), osteoporosis, osteosclerosis, osteomalacia, and soft-tissue and vascular calcification (5).

Sacroiliac involvement like subchondral abnormalities, particularly in the ilium, which consisted of resorption of bone, substitutive fibrosis, and thickening of remaining trabeculae, apparent overlying articular cartilage degeneration and, finally "pseudo-widening" of the joint space noted in ante and post-mortem radiographs simulating the findings in early ankylosing spondylitis have been previously shown in renal osteodystrophy by means of roentgenography and pathology (6,7).

We, herein, presented a FMF patient on hemodialysis with secondary hyperparathyroidism who developed sacroiliac joint disease during follow-up.

Case Report

A 47 year old male admitted to our clinic, suffering from low back pain and morning stiffness. His complaints were of 2 years of duration. He had morning stiffness that did not resolve at rest. His past medical history revealed end stage renal disease (ESRD) and FMF, all of which were diagnosed seven years ago simultaneously. He has been receiving renal replacement therapy as hemodialysis since the diagnosis of ESRD. He underwent parathyroidectomy due to refractory secondary hyperparathyroidism last year. The patient did not have symptoms regarding inflammatory bowel disease, psoriasis and ocular disease. He had no familial history of spondyloarthropathy. He was a non-smoker.

On physical examination, vital signs were stable. Low back pain measurement with visual analog scale (VAS) (0-10) was 7 and morning stiffness was approximately 1 hour. On locomotor system examination, lumbar movements were limited (schoeber test:3 cm). Chest expansion was found as 5 cm (normal according to age and gender). Measurements regarding distances from tragus to wall, occiput to wall and finger to floor were 18 cm, 9 cm and 24 cm, respectively. Bilateral Mennel and Gaenslen sacral compression tests were both positive.

On laboratory examination, erythrocyte sedimentation rate and serum C-Reactive Protein level were in normal ranges (2 mm/h and 0,2 mg/dl, respectively). Rheumatoid factor and serum anti-nuclear antibody level were of non-diagnostic. Serum alkaline phosphatase level was 377 (38-126) U/l and intact parathormone was 9,02 (10-65) pg/ml (that level was 2031 pg/ml just before parathyroidectomy). Brucella agglutination test was negative. Hepatitis serology was all negative for hepatitis B and C. PPD test was also non-diagnostic. Both of HLA-B27 and MEFV mutation for FMF were all positive.

On radiologic examination, posterior-anterior chest X-Ray was normal. Bilateral iliac surfaces of the sacroiliac joints in anterior-posterior pelvic radiograph revealed

increased sclerosis and widened joint space (Figure 1). Cervical spine lateral radiograph depicted osteophytes and irregularity at the vertebral end plates adjacent to the C5-6 disc together with C5-6 disc height loss (Figure 2). On Lateral thoracic radiograph, vertebral osteoporosis, a slight increase in thoracic kyphosis, vertebral osteophytes, and slight irregularity in the vertebral end plates were noticed (Figure 3). Magnetic

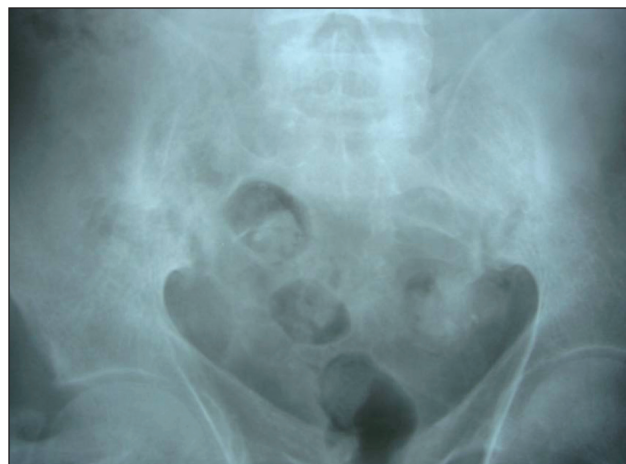

Figure 1. Anterior-posterior pelvic X-ray depicting increased sclerosis and widened joint spaces of the bilateral sacroiliac joints.

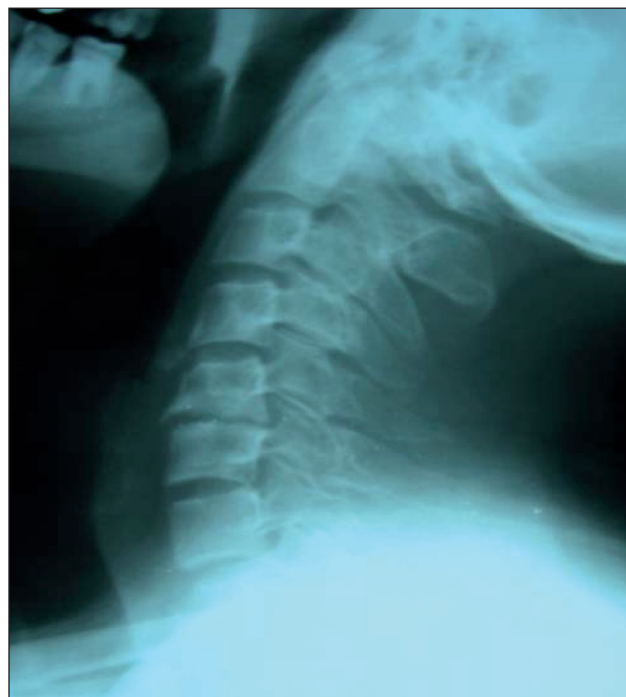

Figure 2. Cervical X-ray demonstrating osteophytes and irregularity at the vertebral end plates adjacent to the C5-6 disc together with C5-6 disc height loss.

resonance imaging revealed sclerosis and erosion at iliac bone surfaces of the sacroiliac joints and widened joint space at coronal STIR image (Figure 4). Furthermore, coronal T1-weighted image showed sclerosis, cortical irregularity and erosions at the surfaces of the iliac bones accompanying expansion in sacroiliac joint distances (Figure 5).

On clinical follow-up, the patient was ordered dexketoprofen trometamol twice a day in addition to colchicine treatment, due to short-acting property. In addition, the patient underwent a physical therapy program including breathing and postural exercises for a period of fifteen days. On the examination a month later, there was a significant reduction in morning stiffness (10 minutes) and pain (VAS:2) complaints.

Discussion

The joint involvement occurs in 70–75% of patients with FMF. Another potential but rare form of involvement is spondyloarthropathy (SpA) (4,8). Patients with

spondyloarthropathy accompanying FMF may have unilateral or bilateral sacroiliitis (4,8). In addition, inflammatory low back pain, relapsing enthesitis and minimal changes in facet joints might be recorded (9,10). The association of HLA-B27 seropositivity, SpA and FMF arose different opinions in the literature. First, the presence of HLA-B27 seropositivity and ankylosing spondylitis in a FMF patient can be considered as a random (11). Second, HLA-B-27 positivity might be a factor aggravating spondylitis in the FMF patients (12,13). In a recent study, the prevalence of sacroiliitis in patients with FMF was 7% and the prevalence of sacroiliitis in patients who are positive for HLA-B27

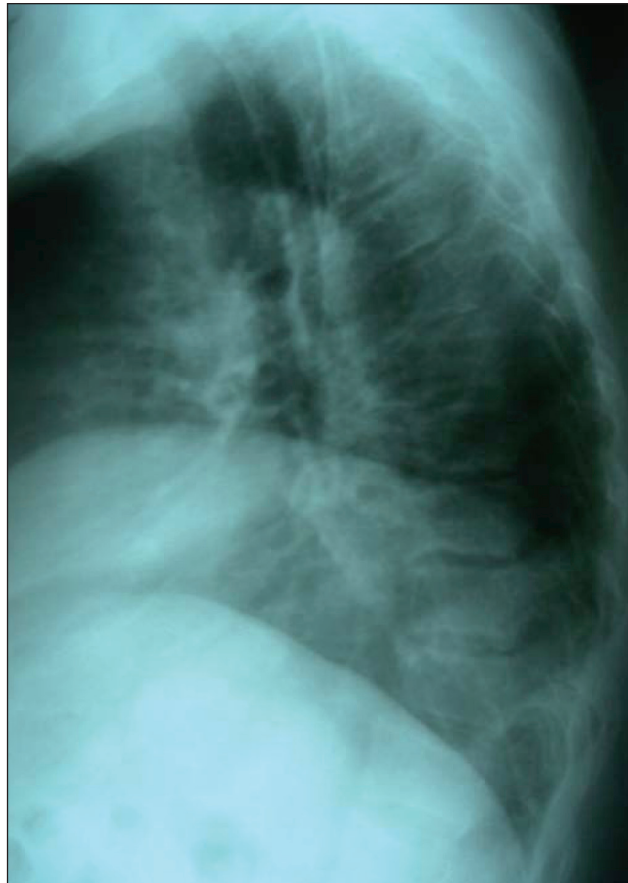


Figure 3. Lateral chest X-ray showing vertebral osteoporosis, a slight increase in thoracic kyphosis, vertebral osteophytes, and slight irregularity in the vertebral end plates.

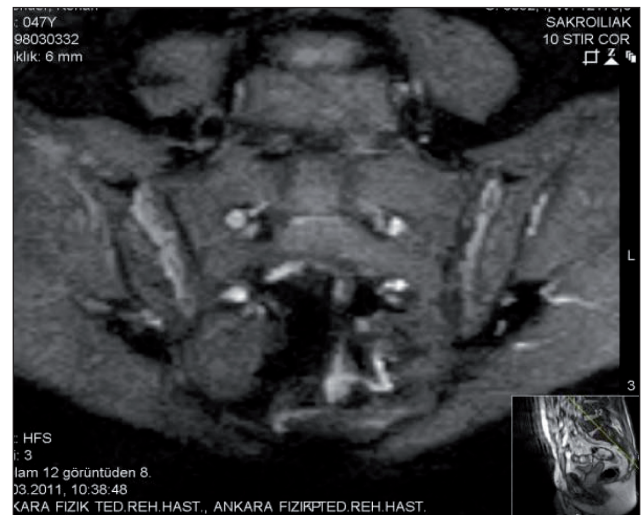


Figure 4. Sacro-iliac MRI depicting sclerosis and erosion at iliac bone surfaces of the sacroiliac joints and widened joint space at coronal STIR image.

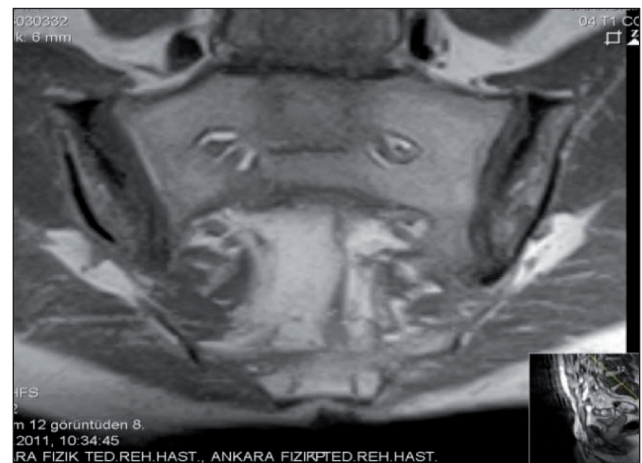

Figure 5. Sacro-iliac MRI. On T1 weighed images, sclerosis, cortical irregularity and erosions at the surfaces of the iliac bones accompanying expansion in sacroiliac joint distances were present.

positivity was approximately 50% (13). That study has also demonstrated a more severe course of spondylitis in patients who are both seropositive for HLA-B27 and MEVF mutation (13). Moreover, the authors have mentioned that involvement of the vertebral column was limited by the involvement of apophysial joints and no evidence of other type of vertebral involvement (squaring) and bamboo cane appearance (13). Similarly, the above mentioned case was serologically positive for both HLA-B27 and MEVF mutation. In addition, radiological studies did reveal neither squaring of the vertebral nor bamboo cane appearance. Hemodialysis patients may experience hypocalcemia due to markedly reduced synthesis of 1.25(OH)₂ vitamin D by renal parenchyme and elevated serum phosphorus levels. Decreased serum calcium level is a well known factor to cause secondary hyperparathyroidism by triggering an increase of the parathormone (PTH) secretion. Radiologic findings of secondary hyperparathyroidism include osteopenia, osteosclerosis, brown tumors, erosive arthritis and heterotropic calcifications (5). In sacroiliac joints; subkondral resorptions, widened joint spaces, apparent irregularities in the iliac surfaces and reactive sclerosis may be observed radiologically. Bilateral and more destructive findings seen in this view may be confused with sacroileal involvement in SpA (14,15,16). In our case, STIR images of the sacroiliac joints were lack of bone marrow edema and were reflecting similar destructive changes observed in secondary hyperparathyroidism. Ankylosing spondylitis is a chronic and systemic disease primarily involving the sacroiliac joints and the spine. As well as the clinical and laboratory findings, the subchondral bone marrow edema, and inflammatory lesions accompanying osteitis associated with definite inflammatory lesions demonstrated in MRI of the sacroiliac joint are also pathognomonic. Moreover, a correlation has been shown between the bone marrow edema by means of MRI and inflammation detected histologically in the spine and sacroiliac joint (17,18). The patient underwent differential diagnostic studies to rule out aetiologic disorders presenting as sacroiliitis. The clinical and laboratory evaluation were not suggestive of Reiter's syndrome, psoriatic arthritis, paraplegia, inflammatory bowel disease, sarcoidosis, intestinal by-pass arthritis, Whipple's disease, tuberculosis, malignancy, brucellosis and pyogenic infections. The major two differential diagnoses for the patient were spondyloarthropathy accompanying FMF and the effect of secondary hyperparathyroidism in the sacroiliac joint involvement. To the best of our knowledge, no previous case with FMF, spondyloarthropathy and secondary hyperparathyroidism has been reported. It may be difficult to diagnose bone diseases clearly in patients with chronic renal disease and especially in patients with renal osteodystrophy (19). In such difficult cases,

the correct diagnosis and the correct treatment options, we would like to emphasize the importance of detailed and accurate imaging techniques in addition to physical examination and laboratory tests.

References

1. Drenth JP, van der Meer JW. Hereditary periodic fever. *N Engl J Med* 2001;345:1748-5.
2. Tsuchiya-Suzuki A, Yazaki M, Nakamura A, Yamazaki K et al. Clinical and genetic features of familial Mediterranean fever in Japan. *J Rheumatol* 2009;36:1671-6.
3. Lidar M, Kedem R, Mor A, et al. Arthritis as the sole episodic manifestation of familial Mediterranean fever. *J Rheumatol* 2005;32:859-62.
4. Langevitz P, Livneh A, Zemer D, Shemer J, Pras M. Seronegative spondyloarthropathy in familial Mediterranean fever. *Semin Arthritis Rheum* 1997; 27: 67-72.
5. Murphey MD, Sartoris DJ, Quale JL, Pathria MN, Martin NL. Musculoskeletal manifestations of chronic renal insufficiency. *Radiographics* 1993;13: 357-79.
6. Resnick D, Dwosh IL, Niwayama G. *J Rheumatol* 1975;2:287-95.
7. Kuhlman JE, Fishman EK, Siegelman SS. Computed tomographic features of renal osteodystrophy *Orthop Rev* 1989;18:1290-5.
8. Borman P, Gökođlu F, Taşbaş O, Yılmaz M, Yorgancıođlu ZR. Familial Mediterranean fever-related spondyloarthropathy. *Singapore Med J* 2009;50:16-9.
9. Bodur H, Uçan H, Seçkin S, Seçkin U, Gündüz OH. Protracted familial Mediterranean fever arthritis. *Rheumatol Int* 1999;19: 71-3.
10. Ozgocmen S, Ozçakar L, Ardicoglu O, Kocakoc E, Kaya A, Kiris A. Familial Mediterranean fever responds well to infliximab: single case experience. *Clin Rheumatol* 2006;25:83-7.
11. Keleş I, Aydın G, Tosun A, İnal E, Keleş H, Orkun S. Familial Mediterranean fever and ankylosing spondylitis in a patient with juvenile idiopathic arthritis: a case report and review of the literature. *Rheumatol Int* 2006;26:846-851.
12. Ben-Chetrit E, Levy M. Familial Mediterranean fever. *Lancet* 1998;351:659-64.
13. Kaşifođlu T, Calişir C, Cansu DU, Korkmaz C. The frequency of sacroiliitis in familial Mediterranean fever and the role of HLA-B27 and MEFV mutations in the development of sacroiliitis. *Clin Rheumatol* 2009;28:41-6.
14. Sundaram M, Seelig R, Pohl D. Vertebral erosions in patients undergoing maintenance hemodialysis for chronic renal failure. *AJR Am J Roentgenol* 1987;149:323-7.

15. Khalfallah M, Faure A, Hamel O, Cantarovich D, Doe K, Raoul S, Bord E, Robert R. [Dialysis-associated spondyloarthropathy. Case report and literature review]. *Neurochirurgie* 2005;51:165-72.
16. Theodorou DJ, Theodorou SJ, Resnick D. Imaging in dialysis spondyloarthropathy. *Semin Dial* 2002;15:290-6.
17. Appel H, Loddenkemper C, Grozdanovic Z, Ebhardt H, Dreimann M, Hempfing A, Stein H, Metz-Stavenhagen P, Rudwaleit M, Sieper J. Correlation of histopathological findings and magnetic resonance imaging in the spine of patients with ankylosing spondylitis. *Arthritis Res Ther* 2006;8:R143.
18. Bollow M, Fischer T, Reisshauer H, Backhaus M, Sieper J, Hamm B, Braun J. Quantitative analyses of sacroiliac biopsies in spondyloarthropathies: T cells and macrophages predominate in early and active sacroiliitis- cellularity correlates with the degree of enhancement detected by magnetic resonance imaging. *Ann Rheum Dis* 2000;59:135-40.
19. Piccoli GB, Quaglia M, Mezza E, Burdese M, Lacuzzo C, Bechis F, Bianconi L, Anania P, Maddalena E, Jeantet A, Segoloni GP, Salvarani C. Ankylosing spondylitis: a difficult diagnosis in Patients on long-term renal replacement therapy. *J Nephrol* 2002;15:177-82.