

Association of Clinodactyly and Syndactyly: A Pictorial Presentation

Klinodaktili ve Sindaktili Birlikteliği: Resimler Eşliğinde

Oğuz Durmuş¹, Ferhat Cüce², Emre Ata³

¹Van Military Hospital, Department of Physical Medicine and Rehabilitation, Van, Turkey

²Van Military Hospital, Department of Radiology, Van, Turkey

³Gulhane Military Medical Academy, Haydarpaşa Training Hospital, Department of Physical Medicine and Rehabilitation, İstanbul, Turkey

Dear Editor,

Clinodactyly and syndactyly are rarely seen. They restrict digit function and cause aesthetic problems. They can be either an isolated manifestation or part of a syndrome. The treatment options are very limited. We wanted to share the images of a patient with both clinodactyly and syndactyly to make a visual contribution to clinical practice.

A 20 year old male presented with pain and deformities in his fifth finger joints bilaterally and his second and third toe joints bilaterally. He complained that his pain followed excessive use. He reported that his deformities had been present since birth and his family members had no similar deformities. The physical examination was normal other than the bilateral radial deviation of the fifth distal phalanxes (clinodactyly) (Figure 1A) and bilateral adhesions between the second and third toes (syndactyly) (Figure 1C). There was no mental retardation. There was no pathologic finding in his cardiac and urological examinations. Plain radiographs showed clinodactyly of the fifth fingers bilaterally (Figure 1B) and single interphalangeal joints were seen in the second through fifth toes of both feet (Figure 1D). Serological markers and biochemical assays were normal. The patient was given analgesics and physiotherapy for the finger pain. An exercise program was arranged to improve the functional use of his hands. Surgical intervention was planned for the clinodactyly and syndactyly.

Clinodactyly is radio-ulnar angulation of the affected finger. This anomaly most commonly involves the small fingers, but can involve other fingers. Clinodactyly can be familial, syndromic, sporadic, or traumatic (1). The incidence ranges from 1 to 20%. Familial clinodactyly is an autosomal dominant trait. It can be associated with ~60 syndromes, most frequently with Down's syndrome. Some rheumatic diseases and traumas affecting the growth plate can cause clinodactyly (2). Syndactyly is described as the fusion of two adjacent digits. It is classified into different types according to the involvement of skin, bone, tendon, and vascular tissue. It can occur as part of a syndrome (such as Streeter, Apert, and Poland syndromes) or it can be seen as a separate manifestation. Syndactyly is an autosomal dominant disorder and an incidence of around 1 in 2000 live births. It can be

Corresponding Author
Yazışma Adresi

Oğuz Durmuş

Van Askeri Hastanesi, Fiziksel Tıp ve
Rehabilitasyon Bölümü, Van, Turkey

E-mail: durmusoguz@gmail.com

Received/Geliş Tarihi: 28.03.2014
Accepted/Kabul Tarihi: 26.10.2014

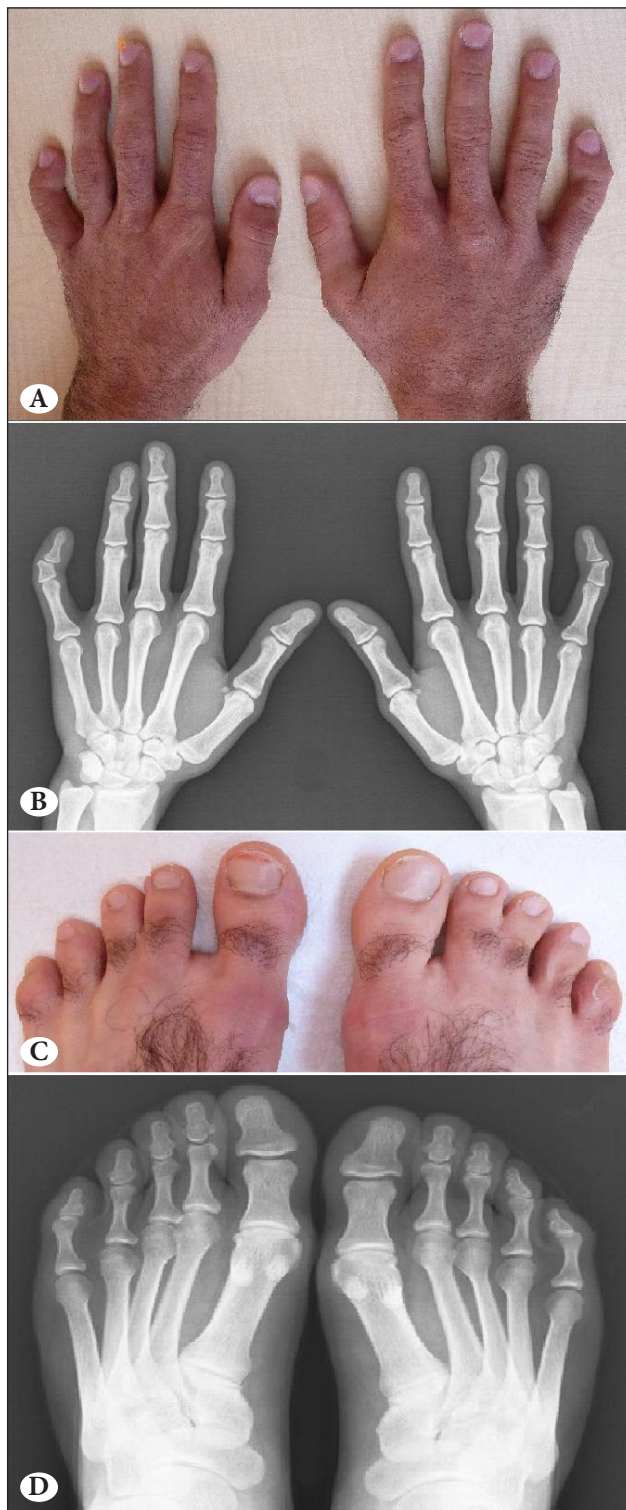


Figure 1. A,B) Clinodactyly of both fifth fingers, C) Syndactyly of the second and third toes bilaterally, D) Single interphalangeal joints in the second to fifth toes of both feet.

seen with finger abnormalities such as clinodactyly (3), but the frequency is not known. These deformities usually cause esthetic problems and functional limitations. The effectiveness of splinting and therapy is usually low (4). Surgical correction might be necessary for deformities according to their effects on daily life.

References

1. Albright SB, Xue AS, Koshy JC, Orth RC, Hollier Jr LH. Bilateral proximal delta phalanges: an unusual presentation of familial congenital clinodactyly. *Hand (NY)* 2011;6:340-3.
2. Flatt AE. The troubles with pinkies. *Proc (Bayl Univ Med Cent)* 2005;18:341-4.
3. Jordan D, Hindocha S, Dhital M, Saleh M, Khan W. The Epidemiology, Genetics and Future Management of Syndactyly. *Open orthop J* 2012;6:14-27.
4. Ty JM, James MA. Failure of Differentiation: Part II (Arthrogryposis, Camptodactyly, Clinodactyly, Madelung Deformity, Trigger Finger, and Trigger Thumb). *Hand Clin* 2009;25:195-213.