

# Osteonecrosis in the Humeral Head: An Overlooked Complication

## Humerus Başı Osteonekrozu: Gözden Kaçan Bir Komplikasyon

Selim Akarsu, Levent Tekin, Ümit Güzelkçük\*\*, Selami Çakmak\*

Gülhane Askeri Tıp Akademisi Haydarpaşa Eğitim Hastanesi, Fizik Tedavi, İstanbul, Türkiye

\*Gülhane Askeri Tıp Akademisi Haydarpaşa Eğitim Hastanesi, Ortopedi, İstanbul, Türkiye

\*\*Gülhane Askeri Tıp Akademisi Tsk. Reh Merkezi, Fizik Tedavi, Ankara, Türkiye

### ABSTRACT

Osteonecrosis results from temporary or permanent loss of blood supply to a part of bone resulting in an ultimate collapse of the affected bony tissue. Steroid therapy is one of the most important causes of avascular necrosis. Because of their anti-inflammatory and immunomodulatory effects, corticosteroids are commonly used at the pre- and/or postoperative period and to treat inflammatory diseases. The patient resented here a 28-year-old woman who has a history of bolus steroid therapy at the postoperative period and two times intraarticular steroid injections in order to reduce the right shoulder pain. But, she had no radiological evolution before the steroid therapies. Overall, osteonecrosis as a complication of steroid therapy developed. At her right shoulder. (*JPMR Sci* 2012;15: 20-2)

**Keywords:** Osteonecrosis, humeral head, steroid therapy

### ÖZET

Osteonekroz, etkilenen kemik parçasının kollapsı ile sonuçlanan geçici olarak kemiğe olan kan akımının kesilmesidir. Steroid tedavisi avasküler nekrozun en önemli nedenlerindedir. Antiinflatuar ve immunomodulatör etkilerinden dolayı kortikosteroidler cerrahi öncesi, sonrasında ve inflamatuar hastalıkların tedavisinde kullanılmaktadır. Bu yazıda cerrahi sonrası bolus tarzda steroid tedavisi alan ve sağ omuz ağrısı nedeni ile iki kez intraartiküler steroid tedavisi uygulanan 28 yaşında bir bayan hasta sunuldu. Fakat steroid tedavileri öncesi herhangi bir radyolojik görüntülemesi yok idi. Sonuçta steroid tedavisinin bir komplikasyonu olarak sağ omzunda avasküler nekroz gelişti. (*FTR Bil Der* 2012;15: 20-2)

**Anahtar kelimeler:** osteonekroz, humerus başı, steroid tedavisi

### Corresponding Author Yazışma Adresi

Selim Akarsu  
Gülhane Askeri Tıp Akademisi  
Haydarpaşa Eğitim Hastanesi, Fizik  
Tedavi, İstanbul, Türkiye

**GSM:** +90 505 766 83 74

**E-posta:** selimakarsu@yahoo.com.tr

**Received/Geliş Tarihi:** 02.02.2012  
**Accepted/Kabul Tarihi:** 16.03.2012

### Introduction

Osteonecrosis which is defined as the in situ death of a bone segment is also known as avascular necrosis (AVN). There are several risk factors for osteonecrosis such as high-dose corticosteroid therapy, excessive alcohol intake, hemoglobinopathies, trauma, malignancy, systemic lupus erythematosus, and hematologic disorders like sickle cell

disease (1). The etiology of the disease can be classified as traumatic or atraumatic. Regardless of the underlying etiology, the common pathway involves disruption of the arterial inflow or the venous outflow of the bone, with resultant osseous cell death. Osteonecrosis of the hip and glenohumeral joint following intra-articular steroid injection has been reported previously (2). But, little is known about shoulder osteonecrosis related to corticosteroid (3,4).

The general treatment strategies for humeral head osteonecrosis include nonoperative modalities for symptomatic early disease, with surgical intervention reserved for more advanced disease or those with stubborn pain (5).

The aim of this article is to present a case with avascular necrosis of the proximal humerus as a complication of steroid therapy.

## Case Report

A 28-year-old woman, with a diagnosis of paraplegia following scoliosis surgery was admitted to our department with a complain of right shoulder pain for the last 5 months. The medical history was otherwise noncontributory. Physical examination revealed tenderness at the right shoulder without a sign of swelling or joint inflammation. Both active and passive range of motion of the shoulder provoked pain. Mild restriction of movement in the right shoulder was also observed. The most common impingement and other specific tests for shoulder (Neer, Hawkin's, painful arc, drop arm tests) were otherwise noncontributory. Neurological evaluation was unremarkable for the upper extremity. The epicrisis of the recent scoliosis surgery showed that the patient had received systemic corticosteroid therapy for a week following the scoliosis surgery. The dose of steroid which has been administered was not exactly known. The patient also stated that in order to reveal pain she had received two intraarticular methylprednisolone acetate (40 mg) injections to her right shoulder with three months intervals and the last injection was 2 months ago.

Laboratory evaluations including complete blood count, levels of calcium, phosphorus, alkaline phosphatase, erythrocyte sedimentation rate, C-reactive protein, uric aside, liver and renal function tests were all normal.

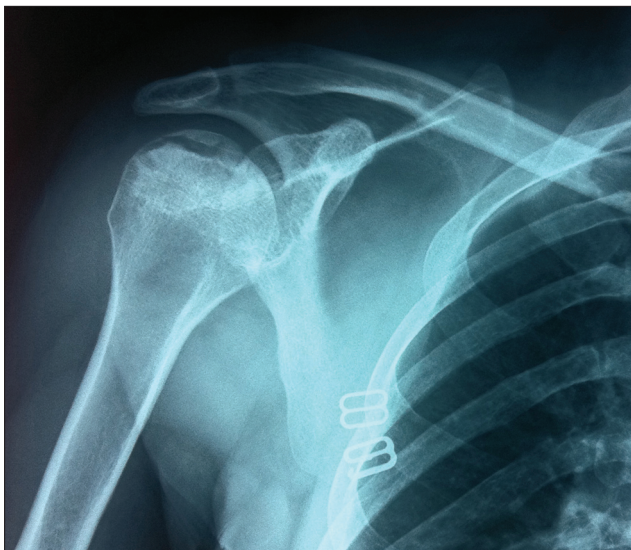


Figure 1. X-ray graphy of the right shoulder show radiolucent area in the humeral head

Radiologic evaluation of the right shoulder showed a radiolucent area in the humeral head (Figure 1). Further evaluation was performed with magnetic resonance imaging (MRI) and right shoulder MRI showed a hypo-intense area, 32x15mm in dimensions, at the humeral head (Figure 2). The finding at the MRI was thought to be compatible with avascular necrosis so the diagnosis of ischemic necrosis was made.

After the diagnosis, the patient was consulted with the orthopedic department and a surgical intervention was not planned for the patient. The patient was referred to hyperbaric oxygen therapy (HBO) and she received 15 sessions of hyperbaric oxygen treatment.

## Discussion

Osteonecrosis results from temporary or permanent loss of blood supply to a part of bone resulting in an ultimate collapse of the affected bony tissue (1). Steroid therapy is one of the most important causes of avascular necrosis. Because of their anti-inflammatory and immunomodulatory effects, corticosteroids are commonly used at the pre-and/or postoperative period and to treat inflammatory diseases such as rheumatoid arthritis, severe asthma, vasculitis and tenosynovitis. Studies suggest that long-term use of oral or intravenous corticosteroids is associated with nontraumatic osteonecrosis (2,3). It is evident in the literature that patients receiving systemic corticosteroid or repetitive intraarticular steroid injections are at risk of developing osteonecrosis (4-6). However, the exact amount of steroid required to cause avascular necrosis is not known. And there is also lack of knowledge about the rate of risk of the steroid therapy on development of avascular necrosis (3).

In our case, the patient has a history of bolus steroid therapy at the postoperative period and intraarticular steroid injection two times in order to reduce the shoulder pain. The patient also declared that the shoulder pain was first aroused during the postoperative rehabilitation period due to progressive exercises. So as to reduce the pain and provide the continuation of the rehabilitation period, first intraarticular

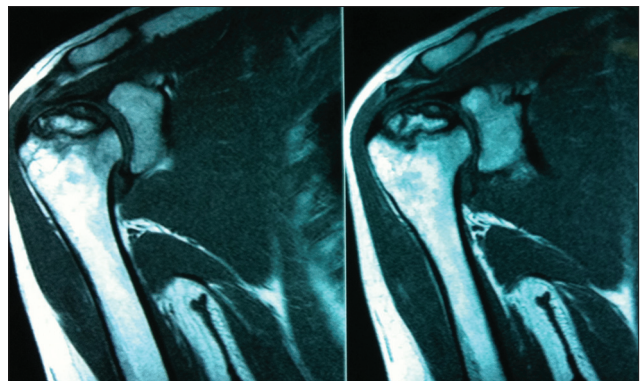


Figure 2. Sagittal MRI image show hypo-intense area in the humeral head

steroid injection was performed. After the injection, the patient stated that she had relief in her symptoms. However, the second injection was performed 3 months later because of the symptoms of the patient relapsed. The dose of steroid administered at the postoperative period is unknown. Perhaps the most important drawback of this case is that the patient had no radiologic evaluation both before the intraarticular injections.

The aim of treatment of AVN is to improve the use of the affected joint, stop further damage to the bone and ensure bone and joint survival (1). HBO restores tissue oxygenation, reduces oedema, and induces angiogenesis. The osteoclast has a high rate of metabolic activity and its function in removing necrotic bone is oxygen-dependent. Moreover, increasing the oxygen tension in hypoxic areas promotes synthesis of collagen, proliferation of fibroblasts and capillary angiogenesis (6). As soon as diagnosed, the patient was directed to the HBO treatment. After the therapy, although the radiological abnormality was continued, the pain significantly decreased and the range of motion was also improved.

As a conclusion, physicians must be aware of the potential risks of high dose steroid usage for long time periods and repetitive intraarticular steroid injections (especially long-acting) as they can cause AVN of the bone. Moreover, a detailed physical and radiologic evaluation

should be performed before intraarticular injections. Suspected lesions must be confirmed by MRI studies. Lastly, it must be kept in the mind that, femoral head is the most frequent but not the only site of this devastating complication and proximal humerus can be affected occasionally. Moreover, it is often unrecognized because of its initial symptoms are usually nonspecific (7). All physicians should be attentive during their practice in order to avoid this complication.

## References

1. Assouline-Dayana Y, Chang C, Greenspan A, Shoenfeld Y, Gershwin ME: Pathogenesis and natural history of osteonecrosis. *Semin Arthritis Rheum* 2002;32:94-124.
2. Laroche M, Arlet J, Mazieres B. Osteonecrosis of the femoral and humeral heads after intraarticular steroid injections. *J Rheumatol* 1990;17:549-51.
3. The natural progression of shoulder osteonecrosis related to corticosteroid treatment. *Clin Orthop Relat Res* 2010;468:1809-16.
4. Gruson KI, Kwon YW. Atraumatic osteonecrosis of the humeral head. *Bull NYU Hosp Jt Dis* 2009;67:6-14.
5. Cruess RL. Steroid-induced avascular necrosis of the head of the humerus: natural history and management. *J Bone Joint Surg Br* 1976;58:313-7.
6. Camporesi EM, Vezzani G, Bosco G, Mangar D, Bernasek TL. Hyperbaric oxygen therapy in femoral head necrosis. *J Arthroplasty* 2010;25:118-23.
7. Moe Kadono, Kazuhiko Kakihana, Ikuyo Endo, et al. Osteonecrosis of the humeral head. *Int J Hematol* 2011;94:222-3