

# Posterior Cord Syndrome Associated with Dural Ectasia, Arachnoid Cyst and Spinal Cord Atrophy in a Patient with Marfan Syndrome

## Marfan Sendromlu Bir Hastada Dural Ektazi, Araknoid Kist ve Spinal Kord Atrofisi ile İlişkili Posterior Kord Sendromu

Özlem Köroğlu Omaç, Murat Karadeniz, Serdar Kesikburun, Evren Yaşar, Bilge Yılmaz, Rıdvan Alaca  
Gülhane Askeri Tıp Fakültesi, Fizik Tedavi ve Rehabilitasyon Anabilim Dalı, Ankara, Turkey

### ABSTRACT

Marfan's syndrome is an otosomal dominant inheritable connective tissue disorder that is associated with multiple abnormalities of the cardiac, skeletal and ocular systems. Although dural ectasia, widening of the spinal canal and neural foramina is a rarely seen condition it is commonly seen in Marfan patient. Posterior cord syndrome caused by lumbosacral dural ectasia, arachnoid cyst and spinal cord atrophy is rare and we discuss this rare association in a 67-year-old man patient with Marfan's syndrome, in this case report it was aimed to emphasize that in Marfan patients with symptoms of Posterior cord syndrome dural ectasia, arachnoid cyst and spinal cord atrophy should be suspected as an etiology. (*J PMR Sci 2010;13:69-71*)

**Keywords:** Rehabilitation, connective tissue, dura mater

### ÖZET

Marfan sendromu kardiyak, iskelet ve oküler sistemde çeşitli anormalliklerle ilişkili otozomal dominant kalıtsal bir konnektif doku hastalığıdır. Dural ektazi, spinal kanalın ve nöral foramenin genişlemesi, nadiren görülen bir durum olmasına rağmen Marfan sendromlu hastalarda sıkça görülür. Lumbosakral dural ektazi, araknoid kist ve spinal kord atrofisinin neden olduğu posterior kord sendromu nadirdir ve biz bu nadir birlikteliği 67 yaşındaki Marfan sendromlu bir erkek hastada tartıştık. Bu olgu sunumunda, posterior kord sendromu semptomları olan Marfan sendromlu hastalarda dural ektazi, araknoid kist ve spinal kord atrofisinden etyolojide şüphelenmek gerektiğinin vurgulanması amaçlanmıştır. (*FTR Bil Der 2010;13:69-71*)

**Anahtar kelimeler:** Rehabilitasyon, konnektif doku, dura mater

### Corresponding Author Yazışma Adresi

Dr. Özlem Köroğlu Omaç  
Gülhane Askeri Tıp Fakültesi,  
Fizik Tedavi ve Rehabilitasyon  
Anabilim Dalı, Ankara, Turkey  
Phone: +90 312 291 17 90  
E-mail: drozlemkoroglu@gmail.com

**Received/Geliş Tarihi:** 19.11.2009  
**Accepted/Kabul Tarihi:** 18.04.2010

### Introduction

Marfan's syndrome is an otosomal dominant inheritable connective tissue disorder that is associated with multiple abnormalities of the cardiac, skeletal and ocular systems (1). Lumbosacral dural ectasia (widening of the spinal canal and neural foramina) is a specific sign of Marfan's syndrome and

is usually asymptomatic. Also in patients with Marfan syndrome, weakened dura due to deformed elastic tissue causes development of arachnoid cysts. Arachnoid cysts are diverticula of the spinal meningeal sac or nerve root sheath. Lazzaro et al reported a Marfan patient with a history of worsening distal sensory motor deficits of the lower limbs due to extradural arachnoid cyst (2). In our case, posterior

cord syndrome was associated with spinal cord atrophy, arachnoid cyst and dural ectasia and we will discuss this rare association in our case report.

Awareness of these complications and development of management protocols is essential since the majority of Marfan patients exhibited neuromuscular symptoms.

### Case Report

We report a 67-year-old man with Marfan syndrome who presented with a 4-year history of worsening sensory and motor deficits of the lower limbs and loss of balance while walking. On sensory examination; pin prick sensation was bilaterally hypoesthetic except for the dermatomes of C2-T11 and L3, light touch sensation was decreased below T12, Temperature sensation was lost below T4 level. Vibration and proprioceptive sensation was lost bilaterally in lower extremities especially prominent in left (Table 1).

Aschille reflexes were bilaterally hypoactive and other deep tendon reflexes were normoactive and no pathological reflexes were detected, his bladder and bowel functions were found to be normal and voluntary anal sphincter function and perianal sensation were also preserved. Neurological examination revealed intact cranial nerve function and there was no dysmetria or dysdiadokokinesia but romberg's sign was positive. He was diagnosed as T-11 paraplegia ASIA-D.

#### Laboratory Assessments Revealed as Following

In his MEP study; Central motor conduction time was bilaterally prolonged, there were signs of conduction defect in the posterior of L4 spinal segment at corticospinal motor tract.

In his tibial SEP: Bilaterally spinal and cortical potentials couldn't be seen. So it was hard to comment about periferic-root conduction but it could be thought as bilateral posterior cord- medial lemniscal sensory tract damage.

In his needle EMG study: A mild lesion was seen at C5-6 and L5 root at the right side.

**Table 1: On motor examination**

	Right	Left
Elbow flexion	5/5	5/5
Wrist extension	5/5	5/5
Elbow extension	4/5	5/5
Finger flexion	5/5	5/5
Small finger abduction	5/5	5/5
Hip flexion	4/5	4/5
Knee extension	4/5	4/5
Ankle dorsiflexion	5/5	5/5
Toe dorsiflexion	3/5	3/5
Ankle plantar flexion	5/5	5/5
Hamstring muscles	5/5	5/5
Hip extensors, adductors and abductors	4/5	4/5

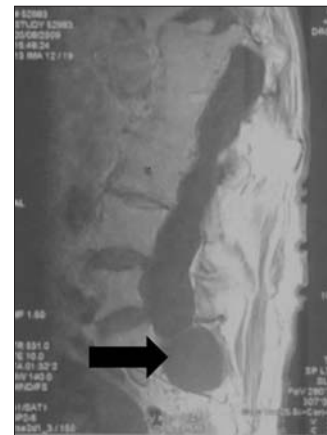
MR imaging revealed significant dural ectasia and vertebral scalloping, arachnoid cyst and central myelopathy and atrophy of spinal cord especially in C7 level (Figure 1,2 and 3).

Brain Computed tomography imaging (CT ) revealed no specific findings.

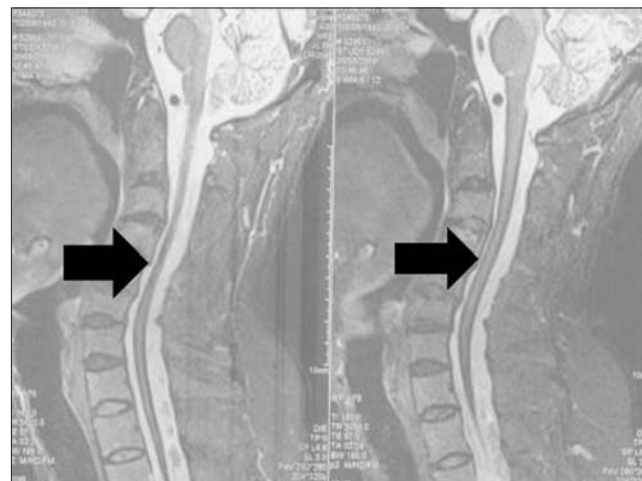Our patient 's diagnose was posterior cord syndrome (PCS). PCS is the least common of the spinal cord injury clinical syndromes. Clinically it is described as a selective lesion of the posterior columns resulting in a loss of proprioceptive and vibration sense below the level of injury, but with preservation of muscle strength, temperature and pain sensation (Figure 4).

Because of the diffuse spinal cord atrophy especially in cervical levels our patient has loss of temperature, pinprick and pain sensation.

PCS has been linked to neck hyperextension injuries, posterior spinal artery occlusion, tumors, disk compression and vitamin B<sub>12</sub> deficiency. In our patient PCS was due to spinal cord atrophy, lumbosacral dural ectasia and arachnoid cyst.



**Figure 1. MR imaging revealed significant dural ectasia and vertebral scalloping, arachnoid cyst**

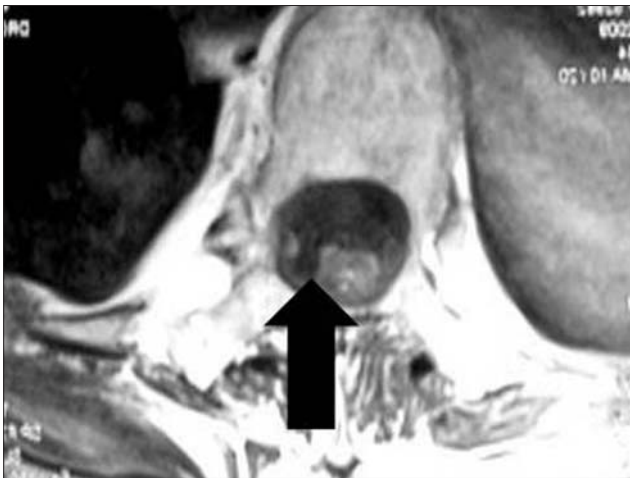

**Figure 2. MR imaging revealed significant central myelopathy and atrophy of spinal cord especially in C7 level**

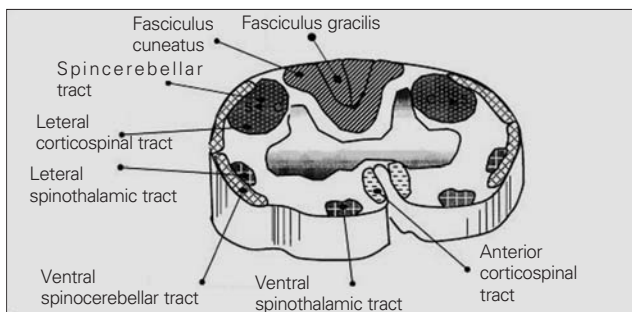
## Discussion

Marfan syndrome might become recognized as an inherited connective tissue disorder with potentially severe neurological complications during ageing. The pain, muscle weakness, muscle atrophy and sensory disturbances illustrate the severe neurological complications which may occur in Marfan syndrome, especially at later age 3.

In marfan patients defective microfibrils that cause weakening and incompetence of the dural sac are the causes of dural ectasia. Dural ectasia is the widening of the spinal canal and neural foramina with evidence of posterior scalloping of



**Figure 3. Transvers MR imaging revealed significant dural ectasia and vertebral scalloping**



**Figure 4. Selective lesion of the posterior columns resulting in a loss of proprioceptive and vibration sense below the level of injury but with preservation of muscle strength, temperature and pain sensation is shown in this figure 4**

the vertebral body (4). In the literature cases of lumbosacral dural ectasia with posterior scalloping of vertebral body causing neurologic symptoms have been reported (5) Rarely dural ectasia is associated with sacral arachnoid cysts which may cause lumbosacral root compression with pain and sphincteric disturbance (6). Also neuromuscular symptoms characterized as myopathy or polyneuropathy or both and signs of lumbosacral radiculopathy may occur in Marfan syndrome (7). Voerman reported three patients with lumbar and/or sacral radiculopathy due to (kypho) scoliosis and dural ectasia with spinal meningeal cysts. Dural ectasia can affect the spinal canal in any plane, but the most common sites are the lumbosacral region. The most common clinical symptoms are low back pain, headache, weakness and loss of sensation above and below the affected limb, rectal and genital pain (5). Dural ectasia may be together with spondylolisthesis, scoliosis and vertebral erosions or fractures and anterior sacral meningocele also may manifest as a pelvic mass<sup>6</sup>. In our case we did not detect such pathologies and in our knowledge there is no case of posterior cord syndrome associated with spinal cord atrophy, arachnoid cysts and dural ectasia in the literature.

In Marfan patients with spinal cord injury dural ectasia, arachnoid cysts and spinal cord atrophy should be suspected as the etiology.

## References

1. Child AH. Marfan syndrome: current medical and genetic knowledge-how to treat and when. *J Card Surg* 1997;12:131-13.
2. Vincenzo Di Lazzaro, Fabio Pilato, Michele Dileone, Giacomo Minicuci, Paolo Profice, Cesare Colosimo, Extradural Arachnoid Cyst With Lumbosacral Cord and Root Compression in Marfan Syndrome; *arch neurol/vol 64, feb 2007*.
3. Voermans NC, Hosman AJ, van Alfen N, Bartels RH, Radicular dysfunction due to spinal deformities in Marfan syndrome at older age: Three case reports.; *Eur J Med Genet.* 2010;53:35-9.
4. De Paepe A, Devereux RB, Dietz HC, Hennekam RC, Pyeritz RE. Revised diagnostic criteria for the Marfan syndrome. *Am J Med Genet* 1996;24:417-26.
5. Foran Jared R. H. Pyeritz Reed E. Dietz Harry C. Sponseller Paul D. Characterization of the symptoms associated with dural ectasia in the marfan patient. *American journal of medical genetics* 2005;34:58-65.
6. Ho NC, Hadley DW, Jain PK, Francomano CA. Case 47: dural ectasia associated with Marfan syndrome. *Radiology.* 2002; 223:767-71.
7. Voermans N, Timmermans J, van Alfen N, Pillen S, Neuromuscular features in Marfan syndrome. *Clin Genet.* 2009;76:25-37.