

# ***The Successful Management of Meralgia Paresthetica Due to Lipectomy and Abdominoplasty with PMR Modalities*** ***Lipektomi ve Abdominoplasti Sonrası Gelişen Meralji Parestetikanın FTR Modaliteleri ile Başarılı Bir Şekilde Tedavisi***

Engin Çakar, Oğuz Durmuş, Ümit Dinçer, Mehmet Zeki Kırıl

Gülhane Military Medical Academy, Haydarpaşa Training Hospital, Physical Medicine and Rehabilitation, Istanbul, Turkey

## **ABSTRACT**

Meralgia paresthetica is a sensory neuropathy of lateral femoral cutaneous nerve due to any injury. Although entrapment at the anterior superior iliac spine is mostly defined clinical reason, injury of the nerve due to abdominal region surgery is one of the other encountered causes. The management of the meralgia paresthetica is not well established yet. Here, a case who had meralgia paresthetica after a lipectomy and abdominoplasty, and successfully managed with low level laser therapy, local surface heat application and electrostimulation which were the common modalities in Physical Medicine and Rehabilitation is presented. (*JPMRS 2009;12:157-8*)

**Keywords:** Meralgia paresthetica, physical medicine, rehabilitation, low level laser therapy, TENS

## **ÖZET**

Meralji parestetika lateral femoral kutanöz sinirin hasarlanmasına bağlı sensoryel bir nöropatidir. Anterior superior iliac spinanın ön tarafında sinirin sıkışması en sık tanımlanan sebep olmakla birlikte, abdominal bölge cerrahisinde sinirin hasarlanması da görülebilen diğer nedenlerden biridir. Meralji parestetikanın tedavisi henüz tam olarak belirlenememiştir. Bu yazıda lipektomi ve abdominoplasti sonrası gelişmiş bir meralji parestetika vakası ve bunun düşük yoğunluklu lazer, lokal sıcak uygulamaları ve elektrostimülasyon gibi sık kullanılan Fiziksel Tıp ve Rehabilitasyon modaliteleri ile başarılı bir şekilde tedavisi sunulmuştur. (*FTR Bil Der 2009;12:157-8*)

**Anahtar kelimeler:** Meralji parestetika, fiziksel tıp, rehabilitasyon, düşük yoğunluklu lazer, TENS

## **Corresponding Author**

### **Yazışma Adresi**

Dr. Engin Çakar

Gülhane Military Medical Academy

Haydarpaşa Training Hospital

Physical Medicine and Rehabilitation

Istanbul, Turkey

Phone: +90 216 542 20 20

E-mail: drecakar@yahoo.com

**Received/Geliş Tarihi:** 07.08.2009

**Accepted/Kabul Tarihi:** 03.10.2009

## **To the Editor,**

A 38 year-old-woman was seen for numbness, itching and a painful burning sensation on the right lateral thigh for the last 14 months. On detailed questioning, she described that she had this complaint after she had a lipectomy and abdominoplasty surgery for her aesthetic concerns approximately 14 months ago. She previously used some non-steroidal anti-inflammatory drugs (NSAID), B vitamin complexes and some topical NSAIDs which were prescribed by her surgeon, but had no alleviation on their complaints. The patient's current

weight was 80 kg and body mass index was 31.2 kg/m<sup>2</sup>. The medical history was otherwise unremarkable.

The physical examination revealed a parenthesis and burning pain with the touch on the skin in the innervation area of the lateral femoral cutaneous nerve (LFCN). There were no further sensory disturbance, and the tendon reflexes and muscle tests of the upper and lower limbs were normal. Electrodiagnostic tests revealed decreased sensory nerve action potential amplitude for the right LFCN, whereas the left side was normal (2.90 uV at right and 8.50 uV at left) (Figure 1). The antidromic technique was used with the placement of

surface electrodes at lateral thigh antidromically to record the action potential following stimulation at the site located one-two centimeter medial to anterior superior iliac spine. The nerve conduction examinations of the peroneal, tibial and sural nerves were normal. Accordingly, the patient was diagnosed as meralgia paresthetica and further more specific assessments were planned. The patient was assessed with Leeds Assessment of Neuropathic Symptoms and Signs (LANSS) scale and it revealed a score of 16 which was >12 and significant for the definition of the neuropathic pain. The patient also was asked to define a rate for her burning pain on a visual analog scale (VAS), with 0 describing no pain and 10 describing worst pain possible, and she rated (7).

Physical therapy including low-level laser therapy (LLLT), transcutaneous electrical nerve stimulation (TENS) and local heat application with hot packs (HP) were applied for 15 sessions (1 session per weekdays, total 3 weeks). An infrared GaAs diode laser (Roland Series IR 27; Elettronica Pagani, Milano, Italy) with a wavelength of 904 nm, frequency range of 5-7000 Hz, pulse duration of 200 nsec, maximum power output of 27 W, average power of 2.4 mW, and spot size of 0.07 cm<sup>2</sup> was used. Laser therapy was applied to three points over the course of LFCN according to a protocol which was described in a previous literature about median nerve entrapment therapy with LLLT (1). The stimulation site of LFCN during the electrodiagnostic study was marked and determined as the first point for LLLT application. The other sites were 1 cm above and 1 cm below of this point. The laser device was used at a power output of 2.4 mW and a pulse frequency of 1000 Hz. The laser probe was applied directly and perpendicularly in contact with the skin for 30 sec at each point. TENS (Class I tip BF; Elettronica Pagani, 2005, Italy) was applied with four electrodes at 60 Hz frequency with 30-45 mA intensity (emission 10 s, pause 5 s, rise time 2 s, fall time 1 s) for 20 minutes at each session. The first two electrodes were placed proximally and the other two electrodes were placed distally at the painful area on the thigh which was described by the patient. The HP was also applied at the same time

with TENS for 20 minutes long. HP were placed over the TENS electrodes and over the LFCN trace which was described previously for the determination of the LLLT application points.

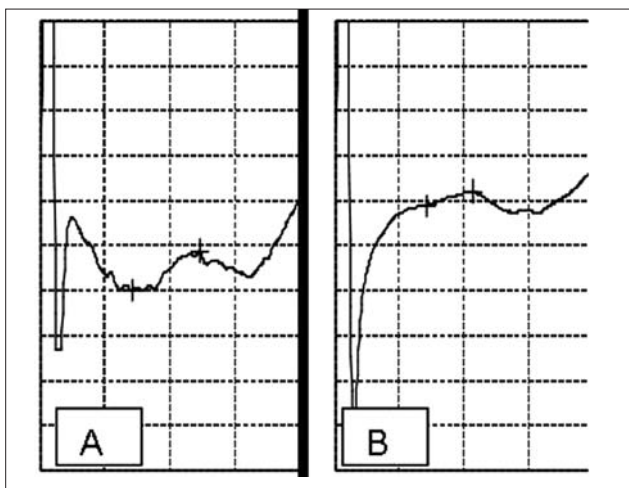
The complaints of the patient were improved at the end of the physical therapy sessions, and LANSS score was 5 and VAS was 0. The patient was invited for controls at 1st and 3rd months and it was seen that she had no further complaints (LANSS score 0, VAS 0).

The reason we report our patient was to highlight the role of physical medicine and rehabilitation in the recovery of the peripheral nerve injury. Nerve injury was a probable complication of near nerve surgical procedures. In this present case LLLT, TENS, HP were used for the management of LFCN injury. These modalities were common in Physical Medicine and Rehabilitation daily clinical practice, although the evidence for the effectiveness of these modalities on nerve regeneration was still insufficient and controversial. The GaAs is directly absorbed in tissues at depths of 1-2 cm and has an indirect effect up to 5 cm. The exact action +mechanisms of LLLT was still unknown, although some proposed physiological effects include acceleration of collagen synthesis, increases in vascularization, reduction of pain, and anti-inflammatory action (2). Successfully usage of TENS in the management of meralgia paresthetica was reported (3), however its exact action mechanism also was not clear. In our case it was also not possible to explain the exact action mechanisms that took place during the healing process. These positive effects might be attributable to the nerve regeneration or to the possible resolution of the adjacent tissues' problems (such as injury or chronic inflammation of ligaments and muscles) which might be the cause of the neuropathy or both of these mechanisms. It was also seemed that the long complaining period (14 months) was not a discouraging factor to apply physical therapy agents for the treatment. Dincer et al. was also reported beneficial effects of LLLT on median nerve entrapment patients whose mean symptom duration was 13.9±5.7 months (1).

In closing, we draw attention of physicians toward the fact that physical medicine and rehabilitation modalities such as LLLT, TENS and HP might be beneficial in the management of peripheral nerve injuries. Furthermore, it is easing factor for the usage of these modalities in confidence that there was no known complication of these modalities in the proposed ranges.

## References

1. Dinçer U, Çakar E, Kiralp MZ, Kilac H, Dursun H. The Effectiveness of Conservative Treatments of Carpal Tunnel Syndrome: Splinting, Ultrasound, and Low-Level Laser Therapies. *Photomed Laser Surg* 2009;29:119-25.
2. Saliba E, Foreman-Saliba S. Low level laser therapy, in: *Therapeutic Modalities in Rehabilitation*, 3rd ed. W.E. Prentice (ed). 2005, New York: McGraw-Hill, pp. 409-32.
3. Çeliker R. Entrapment Neuropathies of the Lower Extremities. *Turk J Phys Med Rehab* 2009;550:30-4.



**Figure 1. The sensory nerve action potentials of left (a) and right (b) lateral femoral cutaneous nerves**